

Development of Gingival Esthetics in the Edentulous Patient Prior to Dental Implant Placement Using a Flangeless Removable Prosthesis: A Case Report

Richard P. Kinsel, DDS¹/Robert E. Lamb, DDS, MSD²

Development of gingival contours found in healthy natural dentitions enhances the esthetic results achieved with implant-supported fixed prostheses. However, this endeavor is frequently difficult to achieve, especially in the completely edentulous patient. Edentulous patients with optimal hard and soft tissue can be treated with a specially designed removable prosthesis that will develop gingival contours prior to implant placement. By means of a transitional complete removable prosthesis with ovate pontics and no labial flange, a natural-looking soft tissue profile can be developed prior to dental implant placement. A minimally invasive tissue punch surgical technique is used to place the implants, which are immediately restored with a 1-piece, cross-arch, provisional fixed prosthesis. This article presents the prosthodontic and surgical protocols utilized to improve the appearance of the definitive implant rehabilitation. (INT J ORAL MAXILLOFAC IMPLANTS 2002;17:866-872)

Key words: dental implantation, dental implants, gingiva, implant-supported dental prosthesis, ovate pontics, temporary denture

The state of the art in implant dentistry and the increasing expectations of patients that their full-arch implant restorations duplicate the appearance of natural dentition continue to challenge the implant treatment team. The surgical and prosthodontic techniques utilized to develop enhanced gingival esthetics in the edentulous patient using a pro-

visional fixed prosthesis supported by single-stage implants have been previously described.^{1,2} Immediate restoration of the implants with a cross-arch fixed prosthesis has been found to be especially important in developing and maintaining soft tissue architecture. The concept of immediate and early loading of dental implants is not new and has been reported by many clinicians as predictable, with implant survival rates comparable to conventional protocols.^{1,3-8}

Edentulous patients exhibiting favorable maxillary alveolar bone quantity in both the vertical and horizontal planes are especially amenable to an implant-supported fixed prosthesis. However, the flat osseous and gingival contours common to patients who have worn conventional complete dentures would preclude the development of natural soft tissue contours, including interdental papillae.

In many patients requiring tooth extractions and/or placement of endosseous implants, there is an opportunity to maintain or enhance the soft tissue contours by means of ovate pontics.^{2,9-14} For

¹Assistant Clinical Professor, Department of Restorative Dentistry, and Director, Implant Dentistry Program, Buchanan Dental Center, University of California at San Francisco; Private Practice, Foster City, California.

²Assistant Professor, Department of Periodontology, University of the Pacific, San Francisco, California; Visiting Assistant Professor, Graduate Periodontics, University of Washington, Seattle, Washington; Private Practice in Periodontics, San Mateo, California.

Reprint requests: Dr Richard P. Kinsel, 1291 East Hillsdale Boulevard, Foster City, CA 94404. Fax: 650-573-8280. E-mail: drcycle@aol.com

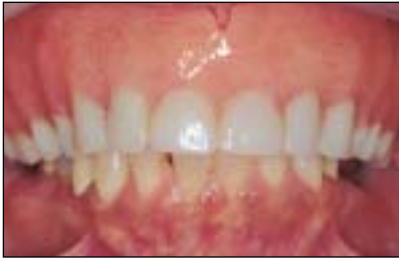
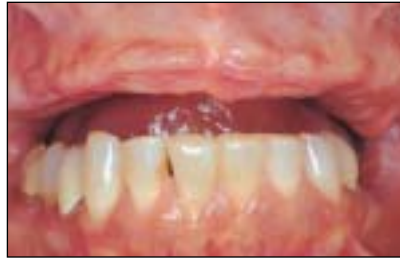
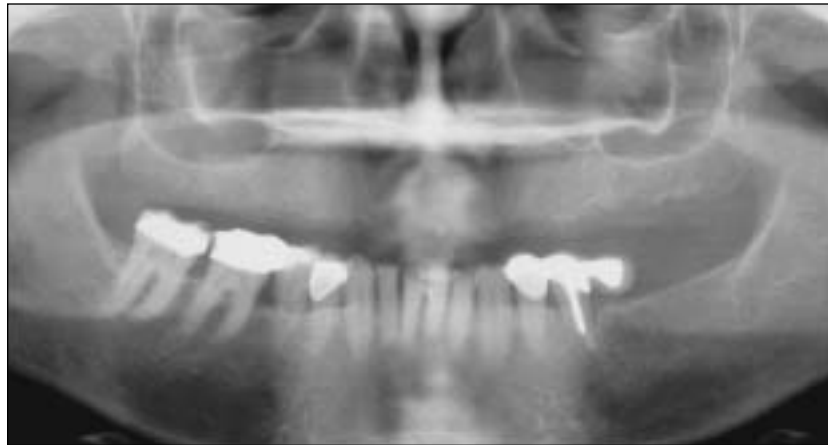
Fig 1a The patient presented with an edentulous maxilla and a conventional complete denture.



Figs 1b and 1c Note the favorable alveolar ridge height and width and relationship relative to the mandibular dentition. Also apparent was the flat gingival topography typically found in long-term edentulous patients.

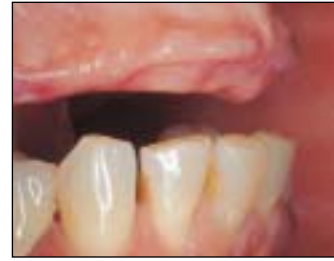

Fig 1d The panoramic radiograph showed adequate bone height mesial to the second premolar positions bilaterally. The inferior border of both antra precluded placement of implants in the molar regions without sinus augmentation.



the edentulous patient with adequate hard and soft tissues or in patients with terminal dentition and insufficient abutments for a transitional fixed prosthesis, a specifically modified removable prosthesis can be used to develop natural gingival contours. Once the gingival frame has been successfully established, a surgical technique that conserves tissue and minimizes disruption of blood supply can be used to place the implants. Immediate loading of the implants with an interim acrylic resin fixed prosthesis is necessary to conserve and further develop the final soft tissue contours.

The use of ovate pontics in both the interim and definitive fixed prosthesis to support facial and interproximal tissues is not a new concept.⁹⁻¹⁴ However, the literature is limited regarding a transitional removable prosthesis using ovate pontics without a labial flange to achieve the same result. The prosthodontic and surgical procedures utilized to improve the appearance of the definitive implant-supported fixed prosthesis are described in this report.

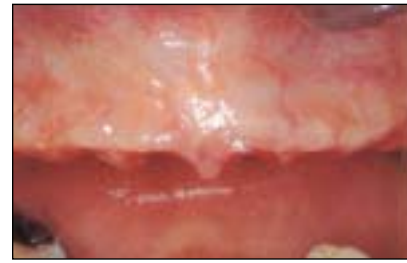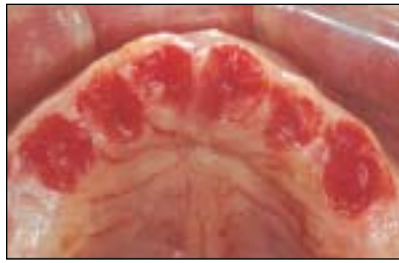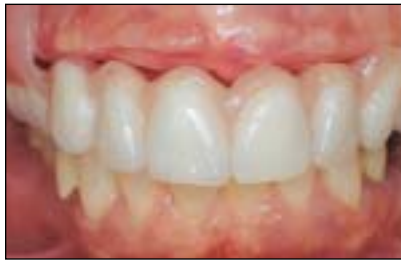PATIENT REPORT

The patient chosen to demonstrate this technique for the maxillary edentulous arch was a 53-year-old

woman presenting with a conventional complete denture. Although the denture had been worn for several years, the patient exhibited favorable alveolar ridge width and height as well as a maxillo-mandibular skeletal relationship that was advantageous for restoration with an implant-supported fixed prosthesis. However, the typical gingival and osseous morphology found in edentulous patients would have led to a poor esthetic result if attention were not given to the gingival contours surrounding the definitive fixed prosthesis (Figs 1a to 1d).

Treatment planning required the use of a trial denture setup to determine the prospective sites for dental implants planned to support the maxillary fixed prosthesis. Additional considerations included biomechanical stability of the prosthesis, distribution of occlusal forces, bone quantity, and potential anatomic restrictions. In this patient, the inferior location of each maxillary sinus prevented the placement of implants distal to the second premolar positions without sinus augmentation. Therefore, the implant sites chosen were the second premolars, canines, and central incisors. To avoid distal cantilevers, the definitive fixed prosthesis would consist of first molars, first premolars, and the anterior sextant.

Fabrication of the transitional removable prosthesis required diagnostic casts mounted with a



Figs 2a to 2c Selected gingivoplasty with a round diamond bur was completed using the previously modified diagnostic cast as a guide.

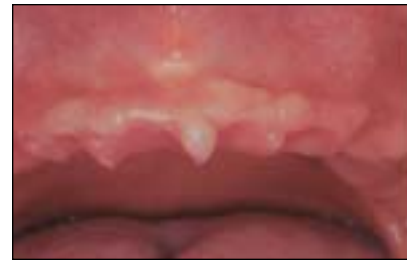
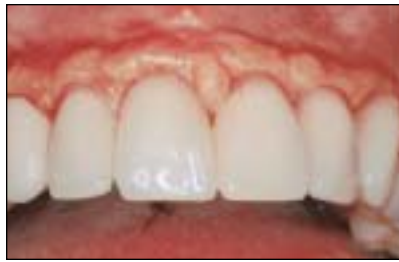
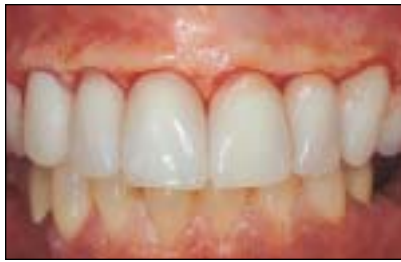Fig 2d The transitional prosthesis was fully seated and the patient was instructed to wear the prosthesis full time, with removal limited to hygiene procedures.

Figs 2e and 2f Six weeks were required to sufficiently develop the soft tissue contours prior to implant surgery.

facebow transfer and centric relation records at the determined vertical dimension of occlusion. The cast was modified by removing at least 3 mm of stone to create sockets at the desired implant and pontic sites. Denture teeth that closely duplicated the mesial and distal dimensions of the desired final prosthetic teeth were set into the recipient ovate concavities. Elimination of the labial flange in the location of the prosthetic teeth duplicates the concept of gingival contouring using a fixed interim prosthesis with ovate pontics. The subgingival portion of the pontic was sufficiently broad to support the facial and interproximal tissues (Fig 2a).

At the time of seating the transitional prosthesis, gingivoplasty of the edentulous ridge at the sites of the ovate pontics was required and corresponded to the modifications made previously on the diagnostic cast. The affected areas were anesthetized with 2% xylocaine containing 1:50,000 epinephrine. A large, round diamond bur (#KS5, NTL, Thuringia, Germany) was used to selectively remove the keratinized crestal tissue, using the previously modified diagnostic cast as a surgical guide (Figs 2b and 2c). Care was taken to narrow the gingival embrasure between the prosthetic teeth so that the remaining soft tissues would completely obturate this space (Fig 2d). The goal was to create gingival embrasures and interdental

papillae that replicated those found surrounding natural teeth. The patient was instructed to wear the transitional prosthesis full time, with removal only for oral hygiene procedures. The use of a denture adhesive was required for retention.

Following the initial soft tissue maturation, the prospective sites were ready for implant placement (Figs 2e and 2f). Precise location of the implant within the confines of the crown abutment was crucial; therefore, a surgical guide was used to facilitate correct placement. The guide was fabricated by duplication of the existing provisional prosthesis in clear acrylic resin.²

Surgical Procedure

When the gingival contours had been established, a flapless surgical technique was employed for implant placement. An open flap technique would likely cause disruption in the periosteum and the blood supply to the underlying bone and could have resulted in apical migration of the gingival profile. A 5-mm tissue punch (Punch Implant Uncovering, Ace Surgical Supply, Brockton, MA), which corresponded to the coronal diameter of the ITI implant (Institut Straumann, Waldenburg, Switzerland), was sectioned in half (Fig 3a) and used to outline the semicircular palatal margins of each implant. The

Figs 3a to 3f The minimally invasive surgical technique utilized in the present patient.

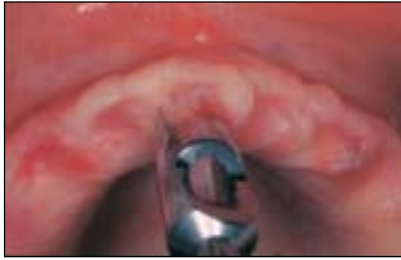
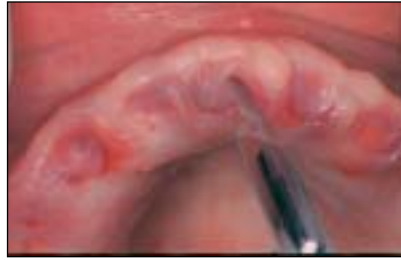
Fig 3a A 5.0-mm tissue punch that had been modified was used to outline the semicircular palatal extension of each implant.



Figs 3b and 3c The labial incision was positioned over the center of the prospective implant sites.

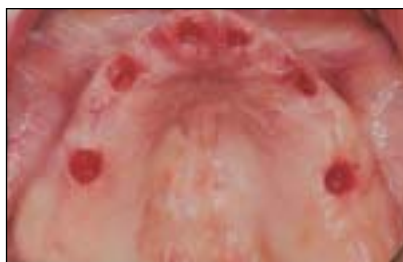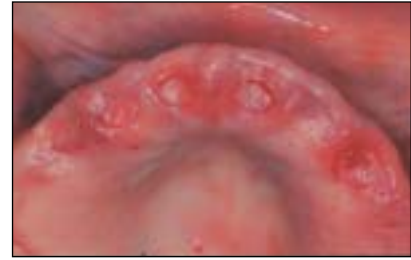


Fig 3d The overlying gingival tissue was removed and the osteotomy completed.

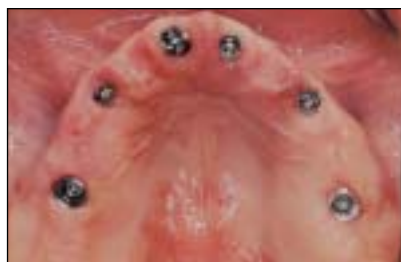

Fig 3e As the tapered implant neck was seated, the excess crestal tissue was moved labially to simulate a natural root prominence.

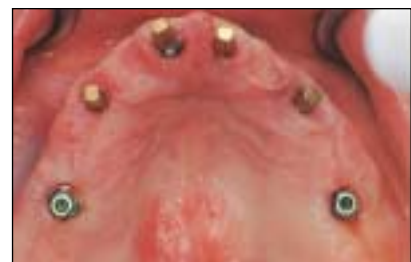

Fig 3f The 4.0-mm solid abutments were then placed into each implant and secured.

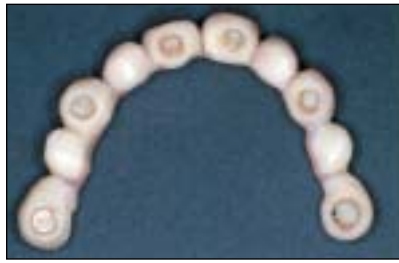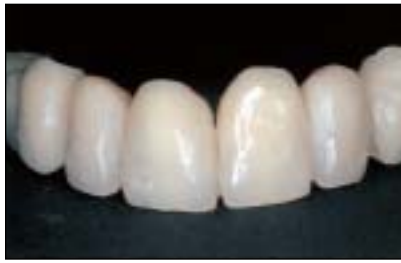labial tissue incision was placed over the center of the implant site and connected with the palatal incision (Figs 3b and 3c). The resulting elliptic shape provided access to the underlying bone and excess attached keratinized tissue that could be repositioned to the labial.

The gingival tissue and periosteum were completely removed and the bone was flattened (Fig 3d). Parallel 2.5-mm-diameter holes traversed the center of each denture tooth of the surgical guide, ensuring proper location of the pilot drills. Placement of the implant coronal platform in both the vertical and horizontal dimensions was crucial to the long-term maintenance of crestal bone. Determination of the appropriate implant length was obtained by placing the depth gauge into the osteotomy sites and measuring the distance from the gingival margin at the labial aspect to the apex. A periodontal probe was used to calculate the gingival height overlying the alveolar crest. Subtraction of these numbers provided the length of implant that would place the microgap at least 2 mm coronal to the bone. The tapered coronal neck of the ITI implant then displaced the excess crestal keratinized soft tissue facially as the implant was seated, thus simulating the root prominence of natural dentition (Fig 3e).

Once the implants had been placed, 4.0-mm-long solid abutments were connected to the implants and tightened to 20 to 35 Ncm (Fig 3f). Angulation concerns that would interfere with placement of the provisional prosthesis were corrected by modification of the solid abutments intraorally with an appropriate bur under copious water spray, as previously described.¹

The palatal acrylic resin was removed from the interim removable provisional prosthesis, which was then modified to incorporate the solid abutments into the denture teeth and relined in situ with an autopolymerizing acrylic resin (Figs 4a and 4b). Correction of the emergence profiles of the abutments was necessary for proper transition from the implant restorative platform and the acrylic resin margins. The narrow interproximal embrasures maintained and enhanced the facial and proximal gingival profiles. The provisional restoration was cemented onto the solid abutments with IRM (Dentsply International, Milford, DE) and the excess cement was thoroughly removed (Fig 4c).

Following osseointegration of the implants, the provisional fixed prosthesis was removed and the solid abutments were tightened to the recommended torque of 35 Ncm. The absence of implant movement and sensation by the patient, in addition



Figs 4a and 4b The palatal acrylic resin was removed from the initial transitional prosthesis, and the pontics over the abutment sites were relieved to allow in situ relining with an autopolymerizing acrylic resin.

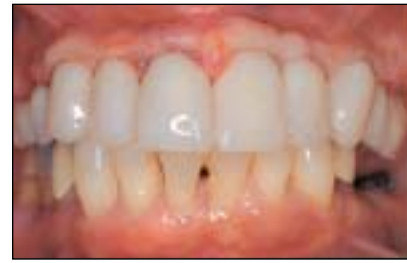

Fig 4c Careful shaping of the gingival embrasures and emergence profiles was required to maintain and further enhance the soft tissue. The converted provisional fixed prosthesis was cemented onto the solid abutments.

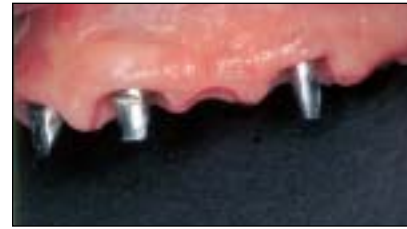
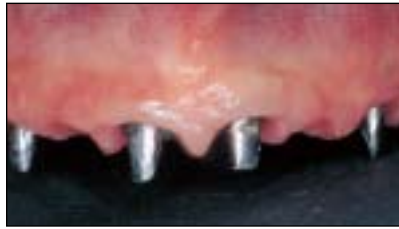
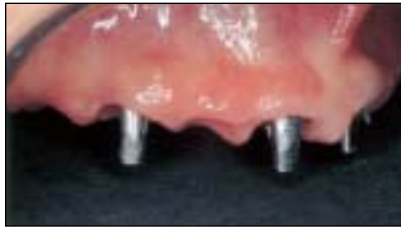Fig 5a Once the implants were osseointegrated, the solid abutments were tightened to 35 Ncm and the final preparations were completed. The gingival frame that was developed has the clinical appearance of the soft tissues and interdental papillae surrounding a natural dentition.

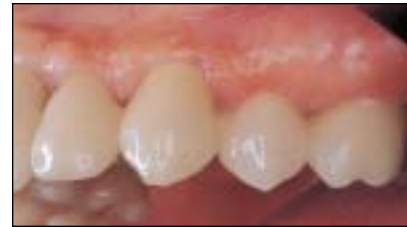
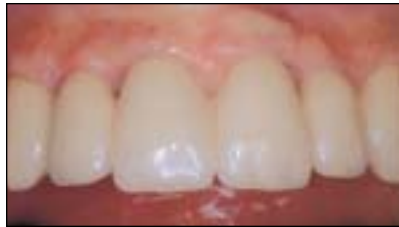
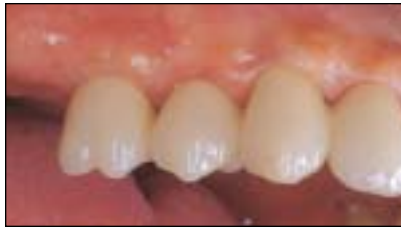Fig 5b The definitive fixed prosthesis was cemented on the solid abutments with a glass-ionomer luting agent (Fuji I, GC Corporation, Tokyo, Japan).

to a favorable radiographic appearance, are general indications of osseointegration.

Final preparation of the solid abutments and, if necessary, the coronal portion of the implant, to achieve esthetic, intrasulcular crown margin placement was completed with carbide finishing burs (#H375R-023, #7408-023, and #ETUF 6.014, Braseler USA, Savannah, GA).^{1,2} The impressions for casts, facebow transfer, and centric relation records were made. A cast of the provisional prosthesis in place served as a template for the framework design and porcelain application. The appearance of the soft tissue profile, following seating of the definitive metal-ceramic fixed prosthesis, duplicated the facial and interproximal contours typically found surrounding healthy, natural dentition (Fig 5a).

The conventional techniques for metal try-in and intraoral indexing with verification of soldered frame-

work accuracy were completed. It was imperative that a soft tissue cast be fabricated to transfer the contour of the soft tissues for proper porcelain application. Special attention was directed toward the contours of the cementsoenamel junction and gingival embrasures of the definitive prosthesis (Fig 5b). The gingival embrasure dimensions had to be biologically acceptable; however, the volume and distance from the contact point to the interseptal bone also needed to facilitate the maintenance of interdental papillae (Fig 6).

DISCUSSION

Edentulous patients, or patients who have terminal dentitions, can be successfully treated with fixed prostheses that are solely implant-supported. However, osseointegration of the dental implant and

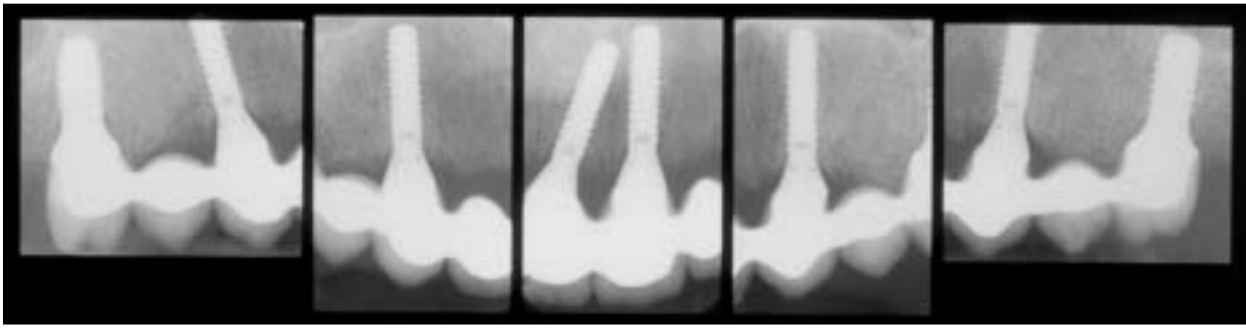


Fig 6 The osseous contour and its relationship to the contact point of each connector of the final fixed prosthesis are shown in the radiographs. The location of the junction of the crown margin/implant microgap was at least 2 mm coronal to the crestal bone. Therefore, no resorption should occur secondary to an anticipated biologic width response. Without osseous resorption, the overlying soft tissue would be expected to remain stable.

completion of a functioning fixed prosthesis are not the only criteria for success. Since the introduction of endosseous dental implants, the patient's expectations have evolved to include a natural-looking gingival frame that enhances the illusion of natural teeth. The protocol for evaluation and prediction of the final gingival contours surrounding single or short-span implant-supported fixed prostheses has been expounded.^{12,13,15-26} The implant team, though, remains challenged to replace the missing gingival contours when several adjacent teeth have been lost or all teeth have been lost.

As described previously^{1,2} and in this report, the use of either fixed or removable interim prostheses designed to maintain or enhance the surrounding soft tissue is valuable in the endeavor to meet patient goals. The prosthodontist or restorative dentist has many techniques available to achieve these objectives prior to implant placement. Treatment planning and communication between the surgeon, prosthodontist, and laboratory technician are of paramount importance.

Additionally, the clinician must be aware that the microgap between the implant and restorative components influences the underlying bone. The soft tissue attachments found surrounding dental implants are comparable to natural dentition. One of the causes of crestal bone loss is result of the unavoidable bacterial contamination within the microgap, consistent with the normal physiologic formation of a biologic width. Also, the optimal distance between adjacent implant restorative platforms is 3 mm.²⁷⁻³¹ If these dimensions are ignored and crestal resorption develops, there is the risk that the soft tissue may recede as well. Therefore, an initial favorable result may cause loss of interdental papillae that would likely not be correctable.

ACKNOWLEDGMENT

Special appreciation is given to David Ho, DDS, and Grace Jotikabhukana, DDS, for their contributions to this article.

REFERENCES

1. Kinsel R, Lamb R. Development of gingival esthetics in the edentulous patient with immediately loaded, single-stage, implant-supported fixed prostheses: A clinical report. *Int J Oral Maxillofac Implants* 2000;15:711-721.
2. Kinsel R, Lamb R. Development of gingival esthetics in the terminal dentition patient prior to dental implant placement using a full-arch transitional fixed prosthesis: A clinical report. *Int J Oral Maxillofac Implants* 2001;16:583-589.
3. Bijlani M, Lozada J. Immediately loaded dental implants—Influence of early functional contacts on implant stability, bone level integrity, and soft tissue quality: A retrospective 3- and 6-year clinical analysis. *Int J Oral Maxillofac Implants* 1996;11:126-127.
4. Tarnow DP, Emitiaz S, Classi A. Immediate loading of threaded implants at stage 1 surgery in edentulous arches: Ten consecutive case reports with 1- to 5-year data. *Int J Oral Maxillofac Implants* 1997;12:319-324.
5. Salama H, Rose LF, Salama M, Betts NJ. Immediate loading of bilaterally splinted titanium root-form implants in fixed prosthodontics—A technique reexamined: Two case reports. *Int J Periodontics Restorative Dent* 1995;15:345-361.
6. Schnitmann PA, Wöhrle PS, Rubenstein JE, DaSilva JD, Wang N-H. Ten-year results for Brånemark implants immediately loaded with fixed prostheses at implant placement. *Int J Oral Maxillofac Implants* 1997;12:495-503.
7. Piattelli A, Paolantonio M, Corigliano M, Scarano A. Immediate loading of titanium plasma-sprayed screw-shaped implants in man: A clinical and histological report of two cases. *J Periodontol* 1997;68:591-597.
8. Ericsson I, Nilson H, Lindh T, Nilner K, Randow K. Immediate functional loading of Brånemark single-tooth implants. An 18 months' clinical pilot follow-up study. *Clin Oral Implants Res* 2000;11:26-33.
9. Winter RR. Esthetic pontics. *Dent Econ* 1994;84:92-93.

10. Miller MB. Ovate pontics: The natural tooth replacement [abstract]. *Pract Periodontics Aesthet Dent* 1996;8:140.
11. Dylina TJ. Contour determination for ovate pontics. *J Prosthet Dent* 1999;82:136-142.
12. Myenberg KH, Imoberdorf MJ. The aesthetic challenges of single-tooth replacement: A comparison of treatment alternatives. *Pract Periodontics Aesthet Dent* 1997;9:727-735.
13. Spear FM. Maintenance of the interdental papilla following anterior tooth removal. *Pract Periodontics Aesthet Dent* 1999;11:21-28.
14. Seibert JS. Treatment of moderate localized alveolar ridge defects. *Dent Clin North Am* 1993;37:265-280.
15. Phillips K, Kois JC. Aesthetic peri-implant site development. The restorative connection. *Dent Clin North Am* 1998;42:57-70.
16. Boudrias P. The implant-supported single-tooth restoration. *Dent Clin North Am* 1993;37:497-511.
17. Tarnow DP, Eskow R. Considerations for single-unit esthetic implant restorations. *Compend Contin Educ Dent* 1995;16:778-784.
18. De Lange GL. Aesthetic and prosthetic principles for single-tooth implant procedures: An overview. *Pract Periodontics Aesthet Dent* 1995;7:51-61.
19. Davidoff SR. Developing soft tissue contours for implant-supported restorations: A simplified method for enhanced aesthetics. *Pract Periodontics Aesthet Dent* 1996;8:507-513.
20. Belser UC, Bernard JP, Buser D. Implant-supported restorations in the anterior region: Prosthetic considerations. *Pract Periodontics Aesthet Dent* 1996;8:875-883.
21. Stein JM, Nevins M. The relationship of the guided gingival frame to the provisional crown for a single-implant restoration. *Compendium* 1996;17:1175-1182.
22. Tarnow DP, Eskow RN, Zamzok J. Aesthetics and implant dentistry. *Periodontol* 2000 1996;11:85-94.
23. Tarnow DP, Eskow RN. Preservation of implant esthetics: Soft tissue and restorative considerations. *J Esthet Dent* 1996;8:12-19.
24. Grunder U, Spielman H-P, Gaberthüel T. Implant-supported single tooth replacement in the aesthetic region: A complex challenge. *Implant Report* 1996;8:835-842.
25. Takei H, Yamada H, Han T. Maxillary anterior esthetics. Preservation of the interdental papilla. *Dent Clin North Am* 1989;33:263-273.
26. Choquet V, Hermans M, Adriaenssens P, Daelemans P, Tarnow DP, Malevez C. Clinical and radiographic evaluation of the papilla level adjacent to single-tooth dental implants. A retrospective study in the maxillary anterior region. *J Periodontol* 2001;72:1364-1371.
27. Cochran DL, Hermann JS, Schenk RK, Higginbottom FL, Buser D. Biologic width around titanium implants. A histometric analysis of the implant-to-gingival junction around unloaded and loaded nonsubmerged implants in the canine mandible. *J Periodontol* 1997;68:186-198.
28. Hermann JS, Cochran DL, Nummikoski PV, Buser D. Crestal bone changes around titanium implants. A radiographic evaluation of unloaded nonsubmerged and submerged implants in the canine mandible. *J Periodontol* 1997;68:1117-1130.
29. Hermann JS, Buser D, Schenk RK, Cochran DL. Crestal bone changes around titanium implants. A histometric evaluation of unloaded non-submerged and submerged implants in the canine mandible. *J Periodontol* 2000;71:1412-1424.
30. Tarnow DP, Cho SC, Wallace SS. The effect of inter-implant distance on the height of inter-implant bone crest. *J Periodontol* 2000;71:546-549.
31. Hermann JS, Buser D, Schenk RK, Schoolfield JD, Cochran DL. Biologic width around one- and two-piece titanium implants. A histometric evaluation of unloaded non-submerged and submerged implants in the canine mandible. *Clin Oral Implants Res* 2001;6:559-603.