

Influence of the Microgap in the Peri-implant Hard and Soft Tissues: A Histomorphometric Study in Dogs

Francisco F. Todescan, DDS, MS¹/Francisco E. Pustiglioni, DDS, MS²/Ana V. Imbronito, DDS, MS¹/
Tomas Albrektsson, MD, PhD, Odhc³/Marco Gioso, MD, MS, DVM, DDS⁴

Purpose: The purpose of this study was to examine the dimensions and relationships of the peri-implant tissues surrounding osseointegrated 2-stage implants placed at different depths in bone.

Materials and Methods: Twenty-four implants were placed in the mandibles of 4 mongrel dogs. A modification of the surgical protocol was introduced so that in group I, implants remained 1 mm above the bone crest; in group II, implants were placed level with the bone crest; and group III implants were countersunk to approximately 1 mm below the bone crest. After 3 months, abutment operations were carried out with the placement of 3-mm standard abutments. Following a healing period of 3 months the dogs were sacrificed. A total of 20 implants were available for histometric analysis. Non-decalcified sections were evaluated for the dimensions of the junctional epithelium, connective tissue band, marginal bone level, and bone-to-metal contact. **Results:** Histologic observations showed a mucosal barrier consisting of keratinized oral epithelium continuous with a thin junctional epithelium facing the implant and abutment surface. Junctional epithelium showed a mean of 1.67 mm for group I, 1.93 mm for group II, and 2.78 mm for group III. These values were not statistically different. The band of connective tissue had a mean of 1.13 mm for group I, 0.92 mm for group II, and 1.60 mm for group III. These values were not statistically different, except for group II versus group III. Bone level had a mean of 2.50 mm for group I, 2.30 mm for group II, and 1.60 mm for group III. These differences were significant between groups I and III. The surface of bone contact along the implant (BMC%) showed mean values of 46.8% in group I, 53.7% in group II, and 49.0% in group III (no significant differences among the 3 groups). **Discussion:** There was a clear tendency of the epithelium and connective tissue to be longer the deeper the implants were placed, although those differences were not statistically significant. Bone loss was smaller for group III (countersink group). This is not in accordance with recent articles which have stated that bone will maintain its biologic width. **Conclusions:** When the microgap between implants and abutments was placed deeper in the bone, additional bone loss did not result. (INT J ORAL MAXILLOFAC IMPLANTS 2002;17:467-472)

Key words: histometry, morphometry, microgap, peri-implant tissues

For many years osseointegrated implant research has basically been focused on the osseous interface and its functional capacity. In recent years,

attention has been given to the tissues that surround the implants, providing a biologic seal.¹⁻⁷ Berglundh and associates,¹ using a dog model, described a soft tissue barrier composed of an epithelial component continuous with a zone of connective tissue. The connective tissue in close contact with the surface of the implant was rich in collagen but poor in cells and vascular structures, resembling scar tissue. This picture was later confirmed by Buser and coworkers,² who used undecalcified sections to examine 1-stage implants. Abrahamsson and colleagues⁴ showed that the previously described tissue organization was similar for different implant systems, not only regarding tissue composition, but also for junctional epithelium and connective tissue dimensions.

¹Lecturer, Department of Periodontology, Dental School, University of São Paulo, Brazil.

²Associate Professor, Department of Periodontology, Dental School, University of São Paulo, Brazil.

³Professor and Chairman, Department of Biomaterials/Handicap Research, University of Göteborg, Sweden.

⁴Assistant Professor, Veterinary School, University of São Paulo, Brazil.

Reprint requests: Dr Francisco F. Todescan, R. Jorge Rizzo 103, São Paulo, Brazil 05424-000. E-mail: ctodescan@uol.com.br

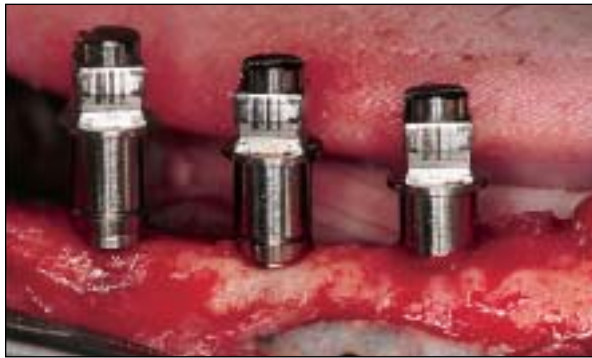

Fig 1a Implant placement. (Left to right) Group I (neck of the implant 1 mm above bone level), group II (neck of the implant at bone level), and group III (neck of the implant 1 mm apical to the bone level).

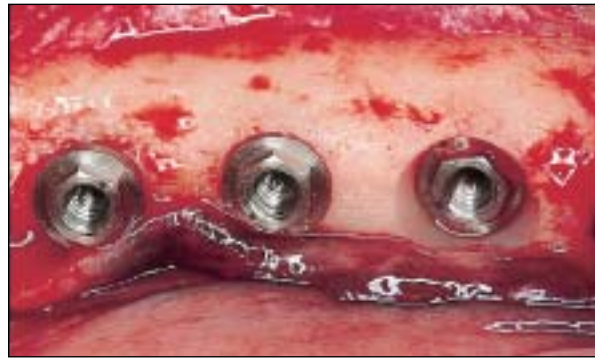

Fig 1b Same situation without implant mounts.

Those reports showed that a junctional epithelium formed an attachment about 2 mm wide to the abutment part of the implant, or to the neck of 1-stage implants. Between this epithelium and the crestal bone, a 1-mm-wide band of connective tissue was established.

The consistency of those results led the authors to consider the possibility of the presence of minimum distances for the junctional epithelium and connective tissues. The dimensions, biologically determined, were similar to those described by Gargiulo and associates⁸ for the human dentition, thereby suggesting the presence of a biologic width around osseointegrated implants. In fact, Cochran and coworkers,⁶ in a histometric study in dogs, suggested that the biologic width exists around unloaded and loaded, non-submerged, 1-stage implants. Berglundh and Lindhe⁹ showed that even in reducing the vertical dimension of the mucosa around osseointegrated implants to about 2 mm, the original dimensions were reestablished after 6 months.

Although all the cited papers have used a dog model and placed the implants according to manufacturers' recommendations, the effect on peri-implant tissues when implants are placed in a position different to that recommended by manufacturers is still unknown. The purpose of this study was to examine the dimensions and relationships of the peri-implant tissues surrounding osseointegrated 2-stage implants placed in different depths in bone.

MATERIALS AND METHODS

Four mongrel dogs approximately 2 years old were used. Extraction of all mandibular premolars was

performed and a 3-month period allowed for osseous regeneration. Three Brånemark System implants were then placed in each side of the mandible (3.75×7 mm; Nobel Biocare, Göteborg, Sweden). A modification of the surgical protocol (recommended by the manufacturer) was introduced so as to place the implants in 3 different positions. In group I, the countersink bur was not used. As result, the neck of those implants was positioned approximately 1 mm above the bone level. In group II, the countersink bur was pressed to 1 mm in bone so that, after placement, the neck of the implant became level with the bone crest. In group III, the countersink bur was used to its reference mark, causing the implant necks to be approximately 1 mm below the bone level (Figs 1a and 1b).

Each animal received 3 implants on each side of the mandible, for a total of 6 implants (2 in each group). The implants were placed in random anterior-posterior distribution. Following a healing period of 3 months, 3-mm standard abutments were connected (Nobel Biocare). Another 3-month period was provided to allow for osseous remodeling. During this period, the implants and teeth were brushed every other day with a soft tooth brush and 0.12% chlorhexidine (Periogard, São Paulo, Brazil). Animals were under the supervision of a veterinary team (University of São Paulo, Brazil) throughout the study. They were housed with free access to water and fed a soft diet to avoid loading the implants. The animals were then sacrificed by an overdose of sodium pentathol and perfused through the carotid artery by a 10% formaldehyde solution. Mandibles were harvested and hemisectioned. Each quadrant was placed in the same fixative solution. The experimental protocol is shown in Fig 2.

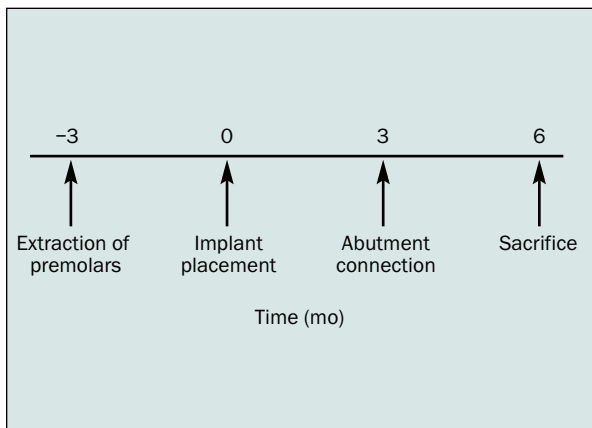


Fig 2 Outline of the study protocol. Four mongrel dogs were used. The mandibular premolars were extracted. After a healing period of 3 months, the implants were placed, and after another 3 months, the abutments were connected. Consecutively, plaque control was performed during a 3-month period. At the end of the plaque control period all dogs were sacrificed.

Histometric Analysis

Blocks comprising the implants and surrounding soft and hard peri-implant tissues were processed for light microscopy using an undecalcified technique.¹⁰ They were cut in a mesiodistal direction through the center of the implants. Slices of approximately 150 μm were initially obtained and ground to about 10 μm . Each section was stained with toluidine blue, and the following parameters were identified and used for linear measurements (Fig 3).

- PM: Peri-implant mucosa
- aJE: Apical termination of the junctional epithelium
- B: First bone-to-implant contact
- A/F: Abutment-implant borderline
- Length of the mucosa (PM-B): Measured from the most coronal point of the peri-implant mucosa (PM) to the first bone-to-implant contact (B)
- Length of epithelium (PM-aJE): Measured from the most coronal point of the peri-implant mucosa (PM) to the most apical cell of the junctional epithelium (aJE)
- Length of connective tissue (aJE-B): Measured from the most apical portion of the junctional epithelium (aJE) to the first bone-to-implant contact (B)
- Marginal bone level (A/F-B): Measured from the abutment-implant borderline (A/F) to the first bone-to-implant contact (B)
- Bone/implant contact (BMC%): Measured thread by thread at the distal and mesial side of every implant

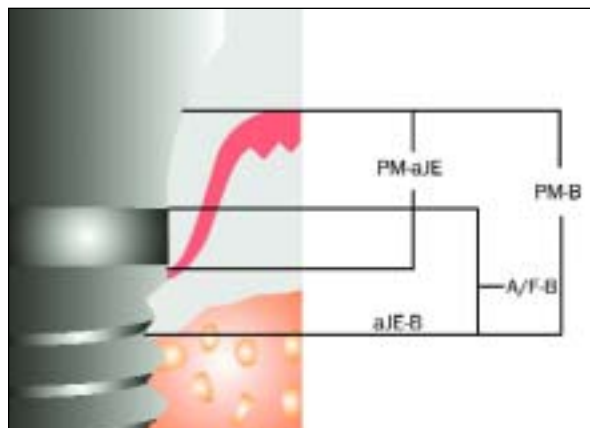


Fig 3 Schematic drawing illustrating the landmarks used for the assessment of linear distances (histometric measurements). A/F = abutment-implant interface; aJE = apical termination of the junctional epithelium; B = marginal bone crest; PM = peri-implant mucosa (PM).

Evaluations were performed using a light microscope (Aristoplan; Leitz, Wetzlar, Germany) equipped with a Microvid unit (Leitz) and a computer-assisted data collection program (Biomaterials Department, University of Göteborg). Results were expressed in millimeters (linear measurements) or percentage (bone-to-metal contact).

Statistical Analysis

To verify whether differences were statistically significant, results were submitted to a mixed-models test.¹¹ This test considered the dependency between observations in the same dog and for the same implant.

RESULTS

All 24 implants healed uneventfully following placement. At second-stage surgery, 3 implants were missing (dog 1/group I; dog 3/group II; dog 4/group II); the cause was unknown. Another implant was eliminated (dog 1/group II) because of clinical mobility. At the end of the plaque control period, the surfaces of the abutments were free from visible plaque, and the peri-implant mucosa showed no signs of inflammation.

A total of 20 implants were available for histometric analysis. The measurements were performed at the mesial and distal sides of each implant and distributed as follows: group I, $n = 7$; group II, $n = 5$; group III, $n = 8$.

Table 1 Mean Values and Standard Deviations (SD) for Epithelium Length (mm), Connective Tissue Length (mm), Mucosa Length (mm), Bone-Implant Contact (%), and Bone Level (mm)

Parameter	n	Mean	SD
Epithelium (PM-aJE)			
Group I	7	1.670	0.650
Group II	5	1.936	0.438
Group III	8	2.781	1.465
Connective tissue (aJE-B)			
Group I	7	1.137	0.476
Group II	5	0.927	0.290
Group III	8	1.636	0.597
Mucosa (PM-B)			
Group I	7	2.811	0.982
Group II	5	2.890	0.543
Group III	8	4.361	1.324
Bone-implant contact (BMC%)			
Group I	7	46.783	11.585
Group II	5	53.690	13.565
Group III	8	49.007	16.351
Bone level (A/F-B)			
Group I	7	2.497	0.414
Group II	5	2.276	0.516
Group III	8	1.678	0.688

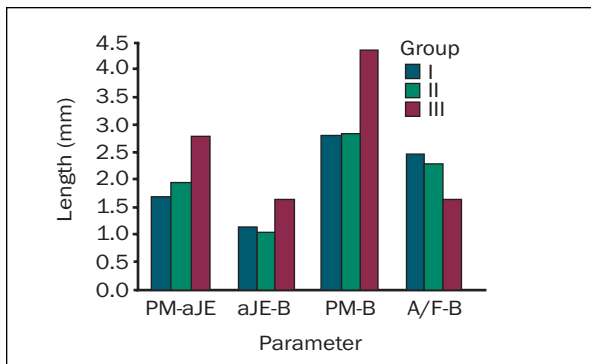


Fig 4 Mean values of PM-aJE, aJE-B, PM-B, and A/F-B for groups I, II, and III.

Histologic Observations

The peri-implant tissues showed similar characteristics to previous descriptions.¹⁻⁴ A mucosal barrier consisted of a keratinized oral epithelium continuous with a thin junctional epithelium facing the implant and the abutment surface. The subjacent connective tissue comprised dense collagen, a few vascular structures, and scattered inflammatory cells.

Histometric Analysis

Results of the histometric measurements are summarized in Table 1. Epithelium presented similar extension measurements regardless of implant posi-

tion ($P = .1282$). The mean values for connective tissue were: group I, 1.137 mm; group II, 0.927 mm; and group III, 1.636 mm. No significant difference was noted between groups I and II ($P = .48$) or between groups I and III ($P = .07$). However, there was a significant difference between groups II and III ($P = .02$). The height of the epithelium along with the height of the connective tissue is the height of the mucosa (PM-aJE), which had a mean value of 2.8 mm in group I, 2.9 mm in group II, and 4.3 mm in group III. There were significant differences when comparing the 3 groups ($P = .02$), between groups I and III ($P = .03$), and between groups II and III ($P = .01$). However, no significant difference was found between groups I and II ($P = .90$).

A comparison among the 3 groups considering the distance between the abutment/implant connection and the bone crest (A/F-B) was made. The mean A/F-B distance was 2.5 mm in group I, 2.3 mm in group II, and 1.6 mm in group III. There was a significant difference when the 3 groups were compared ($P = .03$) and when comparing groups I and III ($P = .01$), but not between groups I and II ($P = .51$) or groups II and III ($P = .08$) (Fig 4).

The surface of bone contact along the implant (BMC%) showed mean values of 46.8% in group I, 53.7% in group II, and 49.0% in group III. There was no significant difference among the 3 groups ($P = .70$).

Fig 5a (Left) Typical specimen of group I (1 mm above the crest). The distance from the abutment/implant borderline to the bone averaged 2.50 mm (original magnification $\times 40$).

Fig 5b (Right) Typical specimen of group III (1 mm below the crest). The distance from the abutment/implant borderline to the bone averaged 1.60 mm (original magnification $\times 40$).

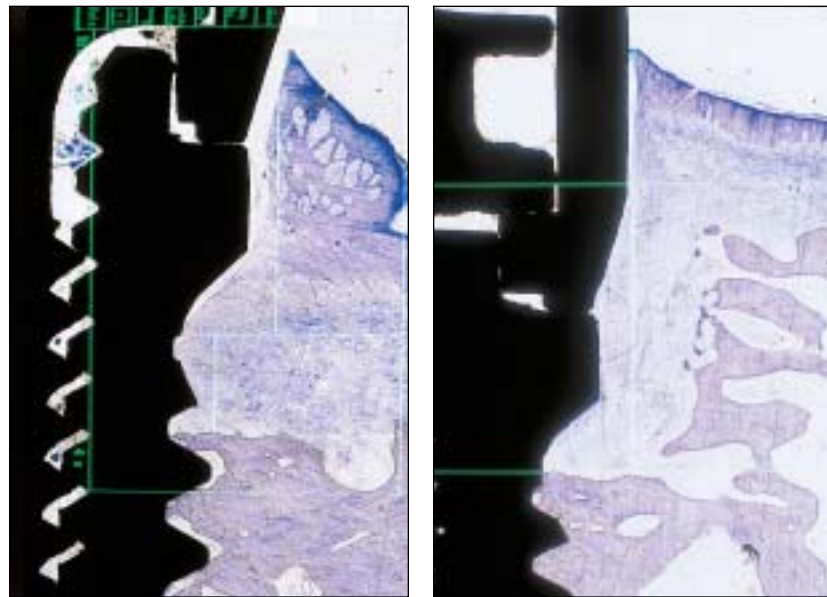
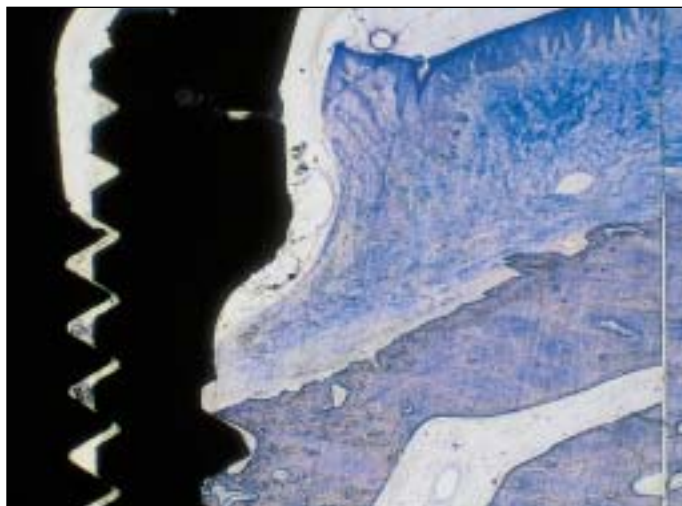


Fig 5c Typical specimen of group II (neck of the implant at bone level). The distance from the abutment/implant borderline to the bone averaged 2.30 mm (original magnification $\times 40$).



DISCUSSION

In the present study, a modification of the surgical protocol was made to investigate whether peri-implant tissues show the same dimensions when implants are countersunk into the bone or left slightly above the cortical bone. The results summarized in Table 1 show that there were no differences for the height of epithelium and connective tissue measured for groups I, II, and III. These results confirm previous findings^{1,4} that the mucosa around implants establishes an attachment of about 2 mm for the epithelial component and about 1 mm for the connective tissue component. There was a clear tendency of the epithelium and connective tissue to be longer the deeper the implants were placed, although those differences were not statisti-

cally significant. The percentage of bone-to-implant contact also showed large variation, but was statistically similar for the 3 studied groups. The level of marginal bone measured from a fixed reference point, the abutment/implant borderline (A/F) to the first bone-to-implant contact (B), showed a statistically significant difference for groups I and III. Thus, if the implant is countersunk, the distance from the abutment/implant borderline to the bone is smaller (Figs 5a to 5c). This is not in accordance with recent articles,^{6,7} which have stated that bone will maintain its biologic width. It is possible that bone behaves differently around dental implants than around natural teeth and can withstand a distance smaller than 2 mm, at least under the conditions studied in this investigation. Furthermore, this observation is not in accordance with the theory of

the microgap,^{6,7} which would allow micro-organisms from the oral environment to proliferate closer to the epithelial attachment and connective tissue, resulting in bone resorption to approximately 2 mm from the microgap. An inflammatory infiltrate would then be expected, as was observed by Hermann and coworkers.⁷ However, it was absent in these specimens. One possible explanation for this could be that the implant system used by Hermann and coworkers⁷ had a different surface texture and a different microgap width (50 μm versus the microgap measured for the 5- μm Brånemark System¹² and used in this research is about 5 μm).

In spite of this, it should be noted that the microgap appears to be larger than 5 μm in Figs 5a to 5c. This could indicate that the microgap has a tendency to open as deformation of components takes place. It is impossible to completely avoid loading on abutments, which could be responsible for opening the microgap. It can only be speculated, since the microgap was not measured and abutment loosening was not observed in this experiment. Uncontrolled loading during early healing, even before implants were exposed, could also cause crestal bone loss. That could explain why bone loss was greater in group II than in group III. Being deeper in the bone, the implants from group III were protected from loading during the early osseointegration phase. Another possibility is that in this study the follow-up period was about 3 months. Ericsson and associates¹³ and Abrahamsson and colleagues¹⁴ described the presence of an inflammatory infiltrate at the abutment/implant gap 4 to 12 months after abutment connection. According to Ericsson and associates,¹³ the presence of inflammatory cells adjacent to the microgap is not related to the presence of plaque.

CONCLUSIONS

Within the limits of this study, it was concluded that the mucosal height and the band of connective tissue were longer when the implants were counter-sunk. The epithelium was statistically similar for the 3 groups. When the microgap between implant and abutment was placed deeper in the bone, additional bone loss did not result. Further research is needed to verify these results over longer time periods and under loaded conditions.

ACKNOWLEDGMENTS

This study was supported by the University of São Paulo. Histology was provided by Nobel Biocare.

REFERENCES

- Berglundh T, Lindhe J, Ericsson I, Marinello CP, Liljenberg B, Thomsen, P. The soft tissue barrier at implants and teeth. *Clin Oral Implants Res* 1991;2:81-90.
- Buser D, Weber HP, Donath K, Fiorellini JP, Paquette DW, Williams RC. Soft tissue reactions to non-submerged unloaded titanium implants in beagle dogs. *J Periodontol* 1992;63:225-235.
- Berglundh T, Lindhe J, Jonsson K, Ericsson I. The topography of the vascular systems in the periodontium and peri-implant tissues in the dog. *J Clin Periodontol* 1994;21:189-193.
- Abrahamsson I, Berglundh T, Wennström J, Lindhe J. The peri-implant hard and soft tissues at different implant systems. A comparative study in the dog. *Clin Oral Implants Res* 1996;7(3):212-219.
- Weber HP, Buser D, Donath K, et al. Comparison of healed tissues adjacent to submerged and nonsubmerged unloaded titanium dental implants. A histometric study in beagle dogs. *Clin Oral Implants Res* 1996;7(1):11-19.
- Cochran DL, Hermann JS, Schenk RK, Higginbottom FL, Buser D. Biologic width around titanium implants. A histometric analysis of the implanto-gingival junction around unloaded and loaded nonsubmerged implants in the canine mandible. *J Periodontol* 1997;68(2):186-198.
- Hermann JS, Buser D, Schenk RK, Higginbottom FL, Cochran DL. Biologic width around titanium dental implants. A physiologically formed and stable dimension over time. *Clin Oral Implants Res* 2000;11(1):1-11.
- Gargiulo AW, Wents FM, Orban B. Dimensions and relations of the dentogingival junction in humans. *J Periodontol* 1961;32(3):261-267.
- Berglundh T, Lindhe J. Dimensions of peri-implant mucosa. Biological width revisited. *J Clin Periodontol* 1996;23:971-973.
- Donath K. Die Trenn-Dünnschliff-Technik zur Herstellung histologischer Präparate von nicht schneidbaren Geweben und Materialien. *Der Präparator* 1988;34(1):197-296.
- Littel RC, Miliken GA, Stroup WW, Wolfinger RD. SAS System for Mixed Models. Cary, NC: SAS Institute, 1996.
- Jansen VK, Conrads G, Richter EJ. Microbial leakage and marginal fit of the implant-abutment interface. *Int J Oral Maxillofac Implants* 1997;12(4):527-540.
- Ericsson I, Persson LG, Berglundh T, Marinello CP, Lindhe J, Klinge B. Different types of inflammatory reactions in the peri-implant soft tissues. *J Clin Periodontol* 1995;22(3):255-261.
- Abrahamsson I, Berglundh L, Lindhe J. Soft tissue response to plaque formation at different implant systems. A comparative study in the dog. *Clin Oral Implants Res* 1998;9(2):73-79.