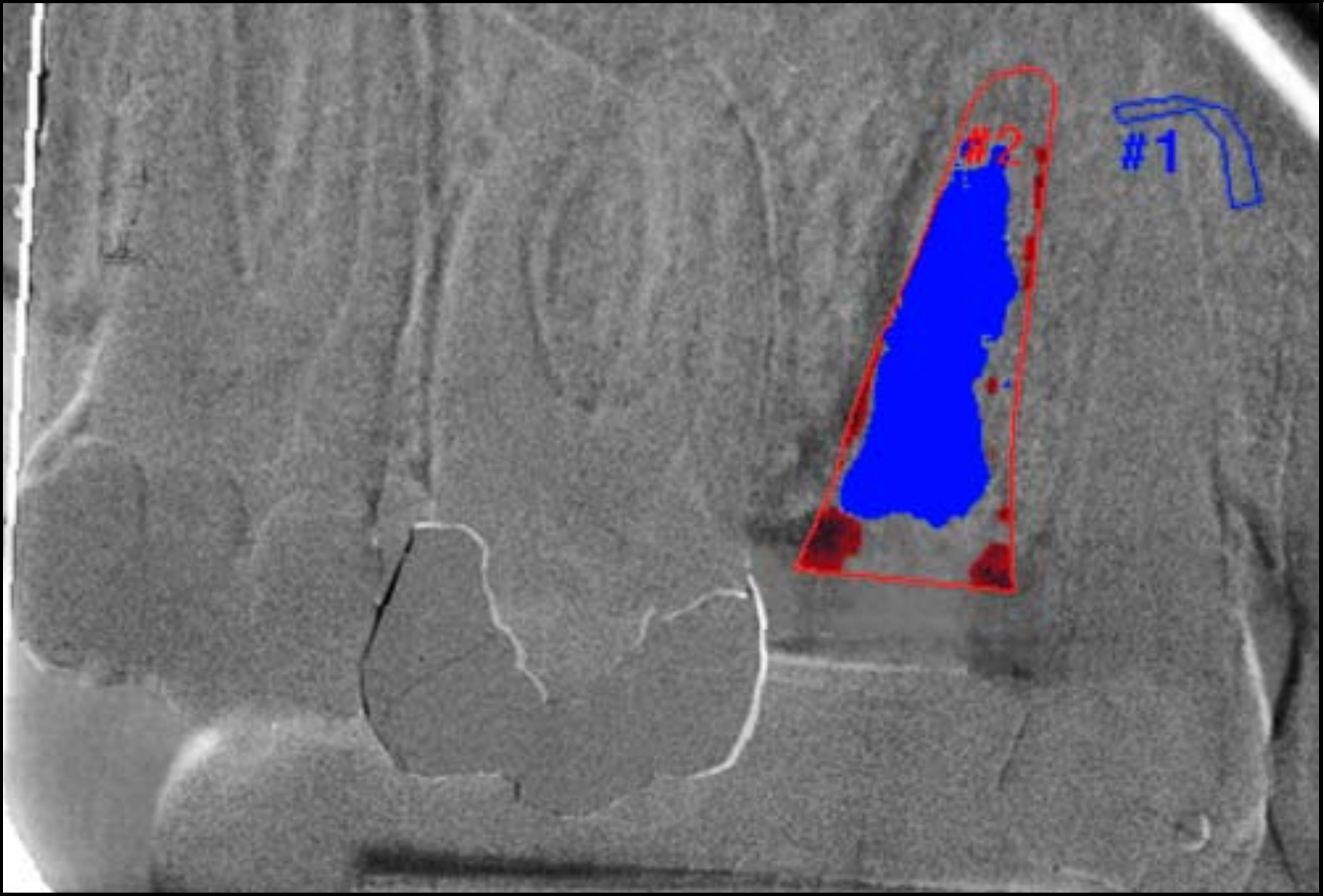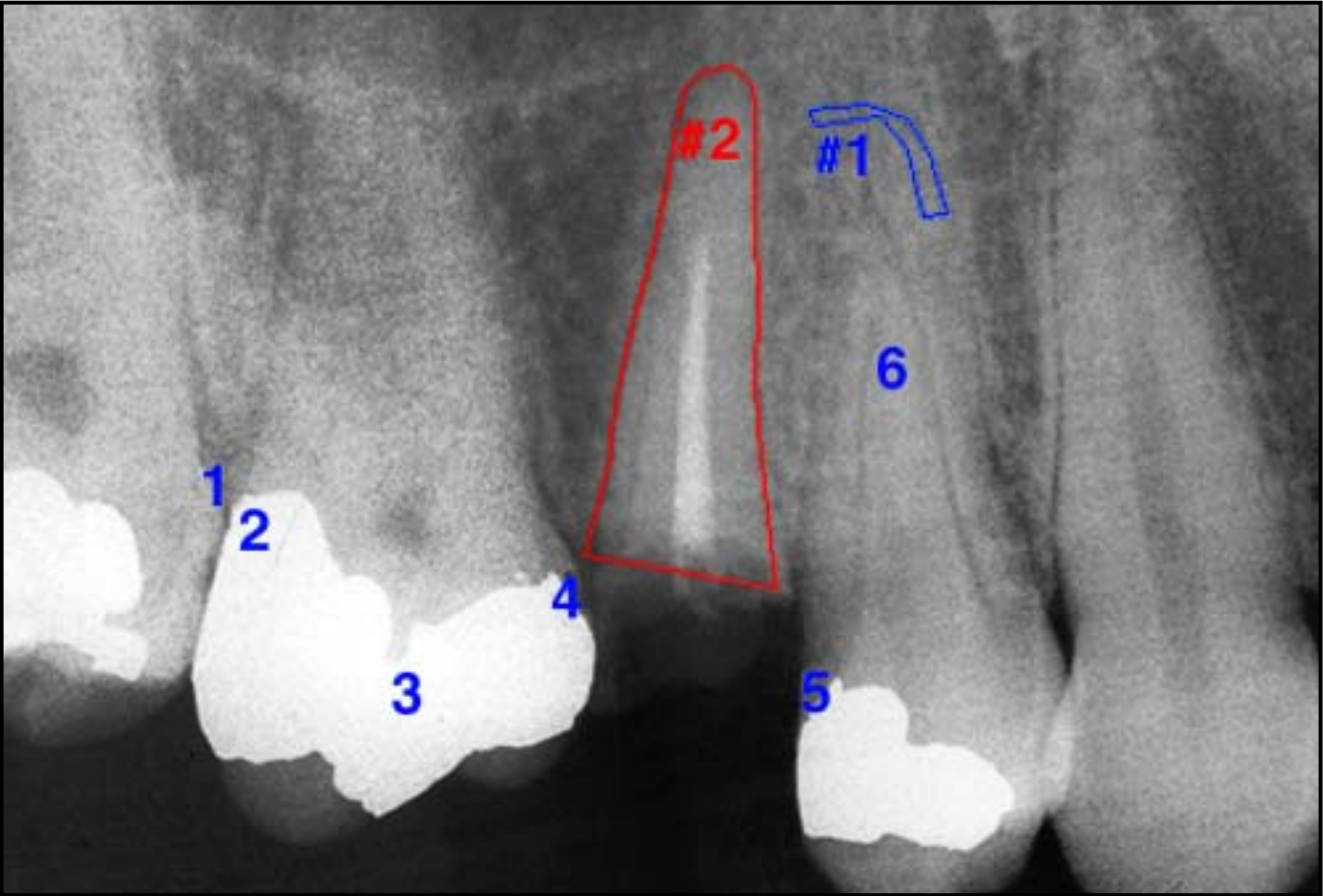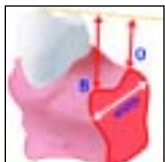


Bone Healing and Soft Tissue Contour Changes Following Single-Tooth Extraction: A Clinical and Radiographic 12-Month Prospective Study



Lars Schropp, DDS*

Ann Wenzel, DDS, PhD, Dr Odont**

Lambros Kostopoulos, MS, DDS, PhD***

Thorkild Karring, DDS, Dr Odont****

Preservation of alveolar bone volume following tooth extraction facilitates subsequent placement of dental implants and leads to an improved esthetic and functional prosthodontic result. The aim of the present study was to assess bone formation in the alveolus and the contour changes of the alveolar process following tooth extraction. The tissue changes after removal of a premolar or molar in 46 patients were evaluated in a 12-month period by means of measurements on study casts, linear radiographic analyses, and subtraction radiography. The results demonstrated that major changes of an extraction site occurred during 1 year after tooth extraction. (Int J Periodontics Restorative Dent 2003;23:313-323.)

*PhD Student, Department of Oral Radiology, University of Aarhus, Denmark.

**Professor, Department of Oral Radiology, University of Aarhus, Denmark.

***Assistant Professor, Department of Oral and Maxillofacial Surgery, University of Aarhus, Denmark.

****Professor, Department of Periodontology and Oral Gerodontology, University of Aarhus, Denmark.

Reprint requests: Dr Lars Schropp, Department of Oral Radiology, University of Aarhus, Vennelyst Boulevard 9, 8000 Århus C, Denmark.
Fax: + 0045 86 19 60 29. e-mail: lschropp@odont.au.dk

Sufficient alveolar bone volume and favorable architecture of the alveolar ridge are essential to obtain ideal functional and esthetic prosthetic reconstruction following implant therapy.¹ Knowledge about the healing process at extraction sites, including contour changes caused by bone resorption and remodeling, is essential. Loss of alveolar bone may occur prior to tooth extraction because of periodontal disease, periapical pathology, or trauma to teeth and bone. Damage of the bone tissues during tooth extraction procedures may also result in bone loss. Finally, alveolar bone atrophy after tooth extraction is a well-known phenomenon.^{2,3}

Histologic investigations in animals⁴ and humans^{5,6} have described the healing of extraction sockets. The gross morphologic changes of the alveolar processes after loss of teeth have been evaluated by cephalometric analyses^{2,7,8} and measurements on study casts.^{9,10} The resorption of the alveolar process after tooth extraction in the maxilla or mandible is significantly larger at the buccal aspect than at

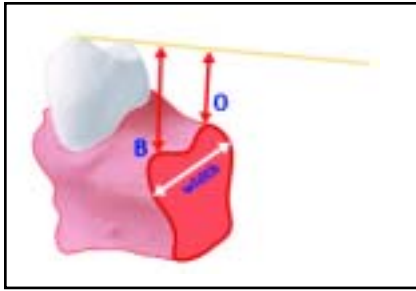


Fig 1 Measurements of alveolar height buccally (B) and orally (O), and width on study casts.

the oral aspect of the jaws⁹; the reduction in width of the maxillary alveolar ridge is greater than the loss in height.¹⁰ This was supported by Lekovic et al,¹¹ who studied bone changes at extraction sites using clinical measurements during operation and measurements on models poured from silicone impressions of the exposed sockets. The maximum loss of tissue contour takes place during the first month following tooth extraction.¹²

Subtraction radiography is a well-established method for the detection of subtle bone changes. The technique was introduced in the 1930s and has been applied to several diagnostic tasks within dental research.¹³ Different subtraction systems, from photographic to digital, have been developed, either operated manually or by more advanced automated systems (for review, see Lehmann et al¹³). In several reports, subtraction radiography has been evaluated regarding

technical facilities and diagnostic effectiveness for the estimation and interpretation of bone mass changes.^{14–17} However, healing of the extraction socket and changes of the alveolar process following tooth extraction have not yet been evaluated by means of subtraction radiography. Therefore, the aim of the present study was to assess bone formation in the alveolus and changes of the contour of the alveolar process following single-tooth extraction.

Method and materials

Forty-six patients (31 women, 15 men), referred for extraction of a maxillary or mandibular premolar or molar and subsequent single-tooth implant treatment, were included in this study. The study teeth comprised 11 maxillary and 10 mandibular premolars and 9 maxillary and 16 mandibular molars. Mean patient age was 45 years (range 20 to 73 years). The reasons for extraction included root fractures, periodontally compromised teeth, endodontic treatment failures, and advanced caries lesions. The patients were given oral and written information regarding the study, and their informed consent was obtained. The research protocol was approved by the Danish Committee for Scientific Ethics as being in accordance with the Helsinki Declaration II.

Following local anesthesia, the teeth were gently luxated with an elevator and carefully extracted with an extraction forceps, attempting to

produce as little trauma as possible to the bone circumscribing the alveolus. The patients, except for two, agreed not to wear any prostheses during the 12-month healing period. Clinical and radiographic evaluation of the extraction site was carried out at baseline (immediately after tooth extraction) and 3, 6, and 12 months following tooth extraction.

Clinical evaluation

The soft tissue and bone contour changes were assessed on study models. Casts were prepared from irreversible hydrocolloid impressions taken immediately after tooth extraction and at the follow-up visits. The distance from the midpoint of the extraction site perpendicular to the line connecting the occlusal surfaces of the adjacent teeth was recorded at the most occlusally situated point both buccally and orally (Fig 1). In addition, the width of the alveolar ridge was measured perpendicular to the tangent of the dental arch at the midpoint of the extraction site as the distance between the most prominent points buccally and orally. All measurements were carried out twice by one investigator using a digital caliper. The reproducibility of the measuring method was evaluated by means of a nonparametric test based on Spearman's rho. Using the mean value of the first and the second measure, the changes over time were calculated and tested by the Wilcoxon matched pairs signed rank test.

The periodontal conditions of the teeth adjacent to the extraction

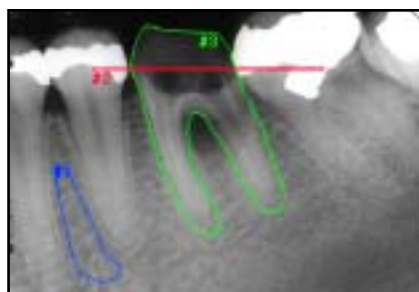


Fig 2a Linear radiographic measurements from reference line (#2) to crestal bone levels: image taken before tooth extraction (I_{BX}). The contour of the tooth (#3) has been drawn in this image. #1 = ROC.

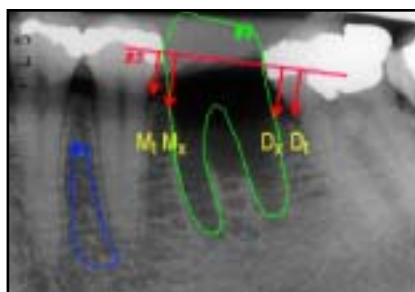


Fig 2b Image taken immediately after tooth extraction (I_{Base}). The tooth contour has been transferred to this image. D_t = mesial aspect of tooth distal to extraction site; M_t = distal aspect of tooth mesial to extraction site; M_x = level of alveolar bone crest at mesial aspect of extraction socket; D_x = level of alveolar bone crest at distal aspect of extraction socket.

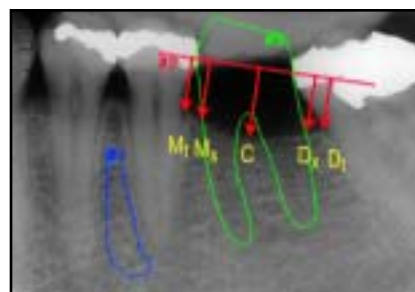


Fig 2c Image taken 12 months after tooth extraction (I_{12}). C = most apically situated point between M_x and D_x .

site were assessed by measuring probing pocket depths and clinical attachment levels at the tooth surfaces mesial and distal to the extraction site using a periodontal probe (Hu-Friedy). The measurements were performed buccally, in the center, and orally at each surface.

Radiographic procedure

Standardized intraoral radiographs (Ektaspeed Plus film, Eastman Kodak) were obtained at the time points described above. To achieve reproducible periapical images, the paralleling technique was used with an occlusal bite index prepared from silicone material (President putty, Coltène) and fixed to a Trollbitten film holder (Trollhatteplast). After placement in the patient's mouth, the bite block was attached to the cone of the radiographic unit by means of a metal muff fitting the outer contour of the cone. This recording device

has been described in more detail elsewhere.¹⁸ The bite index was saved for use at all visits. All radiographs were digitized with a resolution of 300 dpi by a flatbed scanner with a transparency module (Hewlett Packard).

Linear measurements on radiographs

Linear measurements in the digitized radiographs (Fig 2) were performed by means of a computer program designed for linear and angular analyses (PorDiosW, Institute of Orthodontic Computer Sciences).¹⁹

Bone levels at the mesial aspect of the tooth distal (D_t) as well as at the distal aspect of the tooth mesial (M_t) to the extraction site—in cases where these teeth were present—were determined by measuring the distance from a reference line to the bone level at these sites (Figs 2b and 2c). Further, the level of the

alveolar bone crest at the mesial (M_x) and distal (D_x) aspects of the socket of the extracted tooth was measured. The recordings were carried out in the images taken at baseline (I_{Base}) and in those taken 12 months following tooth extraction (I_{12}). In image I_{12} , the most apically situated point between M_x and D_x was recorded (C) (Fig 2c). For assessing the bone levels at the extraction site in these images, the position of the extracted tooth was determined by drawing a contour of the tooth in the image taken before extraction (I_{BX}) (Fig 2a). The "tooth contour" was then transferred to images I_{Base} and I_{12} using the computer program for subtraction radiography. The reference line was drawn in I_{BX} and transferred in a similar manner. All linear measurements were performed twice by the same investigator, and the correlation between the first and second recordings was evaluated by means of Spearman's rho test.

To assess the level of bone healing at the extraction site, the changes of the bone level at the mesial and distal aspects of the socket from baseline to 12 months after tooth extraction were calculated. In addition, the bone level at the mesial and distal aspects of the extraction socket was compared with that of the adjacent teeth. For these calculations, the mean of the first and the second measures was used. The Wilcoxon matched pairs signed rank test was used to evaluate differences between bone level changes over time, and between bone levels at the extraction site and adjacent teeth.

Subtraction radiography

The scanned radiographs were imported into a semiautomated subtraction program, X-Poselt (version 3.01, Torben Jørgensen), and the subtraction process was performed on an IBM-compatible Pentium PC. For alignment of the images, four to nine reference points were defined in each image (Figs 3a and 3b), allowing geometric differences to be corrected to some extent using algorithms for scaling, translation, and rotation. The program operates with a dynamic range of 256 gray shades. By definition, all pixels in a perfect subtraction image of a site without bone changes would have a mean gray level of 128. Bone gain is defined as pixels with a gray level of more than 128 and appears bright in the subtraction image, whereas bone loss is defined as pixels with a

gray level of less than 128 and appears dark. This definition is based on similar radiographic density and geometry in the images to be subtracted, and on the absence of physical background noise.

In the clinical situation, however, thresholds for the pixel values must be determined to compensate for differences in the recording and processing of the radiographs, and to take physical noise into account.²⁰ These thresholds were related to the mean pixel value and the standard deviation (SD) of the histogram distribution of the pixels in a "region of control" (ROC), thereby defining when pixel changes should be regarded as bone gain and loss, respectively, in the "region of interest" (ROI).

- ROI corresponded to the alveolus of the extracted tooth. It was determined by drawing a contour of the root(s) in the image taken before extraction (Fig 3a). The ROI could then be transferred to the baseline image (Fig 3b). The area was subsequently extended so that lamina dura and the septum in cases of multirooted teeth were included in ROI.
- ROC was an area expected not to be involved in bone changes. The area was drawn as large as possible in I_{BX} in a region of trabecular bone and transferred to I_{Base} .

Both regions were automatically transferred to the subtraction image by the program. Pixels with a gray

value within the interval mean value $\pm 2 \times SD$ for the ROC were defined as unchanged. Pixel values above this level corresponded to bone gain, and values below corresponded to bone loss. For better visualization, bone gain in the ROI was colored blue, and bone loss was colored red.

I_{Base} was subtracted from the follow-up images taken 3, 6, and 12 months following extraction (I_3 , I_6 , I_{12}), resulting in the subtraction images $I_3 - I_{Base}$, $I_6 - I_{Base}$, and $I_{12} - I_{Base}$ (Figs 3c to 3e). The statistics of the ROI in these images were exported to the statistical program (SPSS, version 10.0, SPSS), including the mean gray value and the size (using number of pixels as the unit) of the gain, loss, and unchanged areas. The significance of the differences of the mean gray values and the size of the areas over time was tested by the Wilcoxon matched pairs signed rank test. For all statistical tests (both clinical and radiographic data), the level of significance was set to $\alpha = .05$.

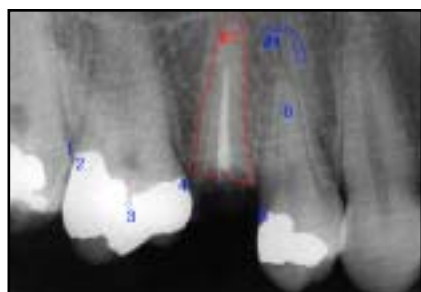

Fig 3a Subtraction radiography: image taken before tooth extraction (I_{BX}). The contour of the tooth (#2, ROI) has been drawn in this image. #1 = ROC.

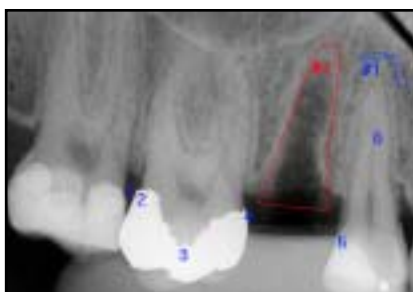


Fig 3b Image taken immediately after tooth extraction (I_{Base}). The ROI has been transferred to this image.

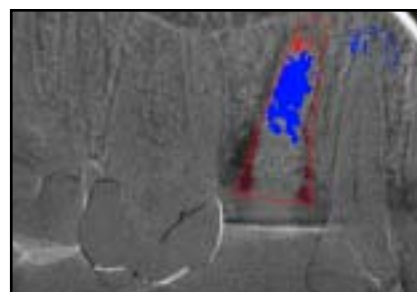


Fig 3c Resulting subtraction images. Blue and red areas in the ROI illustrate bone gain and loss, respectively: $I_3 - I_{Base}$.

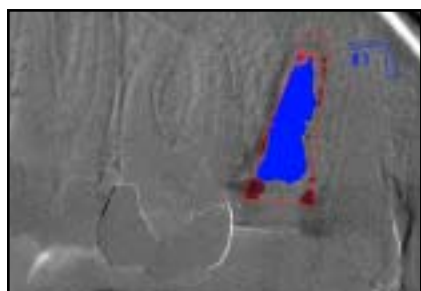


Fig 3d (left) $I_6 - I_{Base}$.

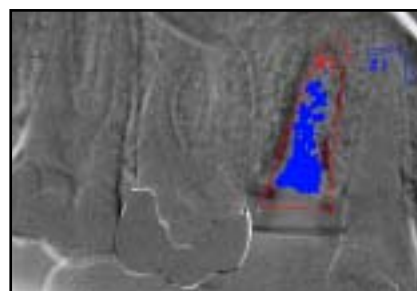


Fig 3e (right) $I_{12} - I_{Base}$.

Results

Clinical evaluation

Two patients withdrew from the study after the 6-month visit. For assessments on models, high reproducibility of the measuring method was found (Spearman's $\rho > .88$; $P < .0001$). Immediately after tooth extraction, the mean width of the alveolar ridge was 12.0 mm (range 8.6 to 16.5 mm). The most occlusobuccal point was located on average 1.3 mm more apically than the occlusooral point. After 12 months of healing, this difference was reduced to 0.2 mm as a result of a tissue gain of 0.3 mm buccally and a loss of 0.8 mm orally (Table 1). Most of the gain

was achieved from 3 to 12 months following extraction, whereas almost the entire loss of height took place during the first 3 months. With regard to the width of the ridge, a reduction of approximately 50% was found, ie, from 12.0 to 5.9 mm (6.1 mm; range 2.7 to 12.2 mm), of which two thirds occurred during the first 3 months of healing. The percentage reduction was somewhat larger in the molar regions than in the premolar regions, and in the mandible compared with the maxilla.

Changes in pocket depth, gingival recession, and attachment level at the tooth surfaces mesial and distal to the extraction site are shown in Table 2. During the first 3 months following tooth extraction, a pocket

reduction of approximately 1 mm was obtained. Hereafter, the pocket depths were almost unchanged. A mean recession of the gingiva amounting to 0.7 mm occurred gradually during the 12-month healing period. A mean attachment gain of 0.3 mm at the tooth surfaces adjacent to the extraction site was found, with no appreciable difference between the changes at the mesial and distal aspects of the teeth next to the extraction site.

Linear measurements on radiographs

The linear measurements recorded twice correlated well (Spearman's

Table 1 Model measurements of mean changes of width and height of alveolar process (mm)*

Region	Baseline-3 mo	3-6 mo	6-12 mo	Baseline-12 mo
All regions				
Height buccally	-0.1 [-0.3;-0.9/0.6]	0.2 [0.2;-0.2/0.5]	0.3 [0.3;0.0/0.5] [†]	0.4 [0.1;-0.6/1.0]
Height orally	-0.8 [-0.8;-1.3/-0.5] [†]	-0.1 [0.1;-0.4/0.4]	0.1 [-0.1;-0.3/0.4]	-0.8 [-0.7;-1.4/-0.2] [†]
Width	-3.8 [-3.4;-5.2/-2.3] [†]	-1.3 [-0.9;-2.2/-0.4] [†]	-1.0 [-0.8;-1.3/-0.3] [†]	-6.1 (12.0-5.9) [-5.9;-7.7/-4.7] [†]
Premolar				
Height buccally	-0.3 [-0.4;-0.9/0.3]	0.2 [0.1;-0.2/0.6]	0.3 [0.3;0.1/0.6] [†]	0.2 [0.0;-0.6/0.9]
Height orally	-0.9 [-1.0;-1.3/-0.5] [†]	0.0 [0.1;-0.5/0.3]	0.1 [0.2;-0.1/0.5]	-0.8 [-0.8;-1.4/-0.3] [†]
Width	-3.1 [-2.9;-3.9/-2.1] [†]	-0.9 [-0.7;-1.3/-0.3] [†]	-0.9 [-0.7;-1.2/-0.4] [†]	-4.9 (10.9-6.0) [-4.9;-5.5/-4.3] [†]
Molar				
Height buccally	0.1 [0.3;-0.9/0.8]	0.1 [0.2;-0.2/0.5]	0.3 [0.1;-0.1/0.5]	0.5 [0.2;-0.6/0.9]
Height orally	-0.7 [-0.7;-1.2/-0.4] [†]	-0.1 [0.1;-0.4/0.4]	0.0 [-0.2;-0.4/0.2]	-0.8 [-0.7;-1.5/-0.1] [†]
Width	-4.5 [-3.7;-6.2/-2.6] [†]	-1.7 [-1.6;-2.8/-0.4] [†]	-1.0 [-0.9;-1.5/-0.3] [†]	-7.2 (13.0-5.8) [-7.6;-8.3/-6.3] [†]
Maxilla				
Height buccally	-0.2 [-0.6;-1.0/0.4]	0.2 [0.4;0.1/0.5] [†]	0.5 [0.3;0.0/0.6] [†]	0.5 [0.1;-0.6/1.4]
Height orally	-0.9 [-1.0;-1.2/-0.5] [†]	0.0 [-0.1;-0.4/0.4]	0.2 [0.2;-0.2/0.5]	-0.7 [-0.7;-1.3/-0.1] [†]
Width	-3.4 [-3.0;-4.6/-1.9] [†]	-1.4 [-0.9;-1.4/-0.4] [†]	-1.0 [-1.0;-1.2/-0.4] [†]	-5.8 (12.7-6.9) [-6.2;-7.7/-4.4] [†]
Mandible				
Height buccally	-0.1 [-0.1;-0.7/0.7]	0.1 [0.1;-0.3/0.5]	0.2 [0.1;0.0/0.5] [†]	0.2 [0.0;-0.7/0.4]
Height orally	-0.8 [-0.7;-1.3/-0.4] [†]	-0.1 [0.1;-0.4/0.2]	0.0 [-0.2;-0.3/0.2]	-0.9 [-0.8;-1.6/-0.2] [†]
Width	-4.2 [-3.7;-5.1/-2.7] [†]	-1.3 [-0.9;-2.3/-0.4] [†]	-0.9 [-0.7;-1.4/-0.3] [†]	-6.4 (11.5-5.1) [-5.8;-7.6/-5.0] [†]

*Absolute width in parentheses; median and 25th/75th percentiles in brackets; positive values = tissue gain; negative values = tissue loss.

[†] $P < .05$.

Table 2 Changes at tooth surfaces adjacent to extraction sites (mm)*

	Baseline-3 mo		3-6 mo		6-12 mo		Baseline-12 mo	
	Mesial	Distal	Mesial	Distal	Mesial	Distal	Mesial	Distal
Pocket depth	-1.1	-1.0	-0.1	0.2	0.1	-0.1	-1.1	-0.9
Gingival recession	0.4	0.3	0.3	0.2	0.1	0.1	0.8	0.6
Attachment level	0.7	0.7	-0.2	-0.4	-0.2	0.0	0.3	0.3

*Mean values for the three sites measured at each tooth; positive values = tissue gain; negative values = tissue loss.

rho > .90; $P < .0001$). The bone levels at the tooth surfaces mesial as well as distal to the extraction site were almost unchanged from extraction to the 12-month visit (a loss of approximately 0.1 mm). At baseline, the mean bone levels corresponding to the mesial (M_x) and distal sites (D_x) of the extracted tooth were located 0.7 mm and 0.3 mm more apically than the level at the mesial

and distal teeth, respectively. After 12-month healing of the extraction socket, the difference in bone levels mesially and distally had increased from 0.7 to 0.9 mm and from 0.3 to 0.5 mm, respectively. The bone level at M_x and D_x after 12 months was situated 0.3 mm more apical than at baseline. This difference was statistically significant ($P < .04$). Furthermore, the bone level at the most

apically situated point between M_x and D_x was located 1.2 mm more apical than at these two sites ($P < .0001$).

Subtraction radiography

Because of lack of useful reference points, the subtraction procedure was not performed in three patients.

Table 3 Descriptives for mean gray values in areas of gain, loss, and no change as defined by thresholds, and size of these areas in pixels

Region	$I_3 - I_{Base}$		$I_6 - I_{Base}$		$I_{12} - I_{Base}$	
	Mean gray value	Area size	Mean gray value	Area size	Mean gray value	Area size
Area of gain						
Median	151.4* [†]	1,644 [‡]	158.0*	2,640 [‡]	161.8 [†]	1,602
25th/75th percentiles	138.2/165.3	492/3,188	146.4/169.1	1,374/3,958	151.5/174.5	689/3,916
Mean	147.4	2,053	154.5	2,812	159.3	2,224
Standard deviation	32.1	1,917	32.4	2,067	33.9	1,690
Area of loss						
Median	101.2	845	107.4	911	114.6	704
25th/75th percentiles	96.4/121.0	148/2,299	97.8/123.7	155/1,610	103.4/128.0	193/1,662
Mean	104.5	1,508	104.0	1,127	109.3	1,537
Standard deviation	27.1	1,770	31.5	1,288	32.3	1,964
Area of no change						
Median	131.1*	5,438	135.2	4,987	139.7*	4,639
25th/75th percentiles	122.9/147.2	4,830/7,022	127.5/148.6	3,663/6,692	126.7/151.9	4,069/7,002
Mean	133.2	6,027	136.7	5,649	140.5	5,778
Standard deviation	19.3	2,319	20.0	2,679	17.7	2,706

* $P < .05$; [†] $P < .02$; [‡] $P < .005$.

In addition, eight patients were excluded from the statistical analysis of the subtraction data because of poor recording reproducibility. The results of the subtraction analysis are described for the remaining 35 patients.

The general observation of bone changes in the extraction sites was that bone formation took place in the extraction alveoli simultaneously with a loss of height of the alveolar crest (Figs 3c to 3e). Most of this bone gain and loss occurred within the first 3 months. In contrast, remodeling of the lamina dura—including the septum in cases of multirooted teeth—was more pronounced in the period from 6 to 12 months after tooth extraction. In approximately one third of the cases,

the area showing bone gain was larger after 6 months than after 12 months of healing. The area of gain was larger after 6 months than after 3 and 12 months (Table 3), and it was larger than the area of loss after 3, 6, and 12 months. The size of the latter area was approximately the same at 3, 6, and 12 months. The mean gray value of both the gain and loss areas increased during the 12 months of healing; the bone became more dense over this period. Using a nonparametric test, it was found that for areas of gain, the mean gray value in images $I_3 - I_{Base}$ and $I_6 - I_{Base}$ ($P < .05$), as well as the mean gray value in images $I_3 - I_{Base}$ and $I_{12} - I_{Base}$ ($P < .02$), differed significantly. Furthermore, the size of the gain area in images $I_3 - I_{Base}$

and $I_6 - I_{Base}$ was significantly different ($P < .005$). For the unchanged area, the mean gray value in images $I_3 - I_{Base}$ and $I_{12} - I_{Base}$ differed significantly ($P < .05$).

Comparing the results of subtraction radiography and the linear radiographic measurements, of the 34 patients who were analyzed by subtraction radiography and followed for 12 months, a reduction of the crest was seen in 26. Crestal bone loss was found in 25 of these also when using linear measurements. In five of the remaining eight patients, agreement between the two methods was found.

Discussion

This prospective clinical trial demonstrated that major changes of an extraction site take place during the 12 months following tooth extraction. The width of the alveolar ridge was reduced by 50% during the observation period. This loss, corresponding to 5 to 7 mm, is in agreement with earlier studies.^{9,10,21} The finding that approximately two thirds of this reduction occurred within the first 3 months after tooth extraction also corresponds to earlier findings.^{10,12,21} When analyzing the extraction sites separately according to region and jaw, there was no major diversity between the sites.

Only slight changes, less than 1 mm, in soft tissue height took place in both jaws during the 12 months of healing. A small increase buccally and a reduction orally were found within the first 3 months. This disagrees with other studies,^{10,12} which, although demonstrating a greater width than height reduction of the alveolar process, reported a height reduction of 2.0 to 4.5 mm. This disagreement may be explained by the fact that those studies involved multiple extractions. Furthermore, the few patients ($n = 3$) examined in one study¹² received an immediate removable partial denture after extraction of the teeth; in the present study, 44 of 46 patients wore no prosthesis in the healing period.

In addition to the analysis of study casts, possible changes in attachment levels at the teeth adjacent to the extraction site were examined clinically. Gingival reces-

sion was less than probing pocket depth reduction 12 months after tooth extraction at the surfaces mesial and distal to the extraction site, showing that a 0.3-mm gain of attachment level was achieved during the 12 months of healing. Despite the minor magnitude of these changes, the results indicate that periodontal health tends to improve at teeth adjacent to an extraction site during the healing period.

In the present material, linear measurements on radiographs showed that the level of the bone generated into the extraction socket never reached the levels at the tooth surfaces distal and mesial to the extraction site. Furthermore, the bone levels at the mesial and distal sites of the extraction socket almost corresponded to the level of the bone generated into the socket 12 months following tooth extraction. These observations suggest that the bone level at the extraction site, rather than the bone level of the adjacent teeth, dictates the level to which the bone crest heals after extraction. Between the mesial (M_x) and distal (D_x) sites of the extraction socket, the morphology of the alveolar crest became curved, with the "lowest" point situated 1.2 mm apical to M_x and D_x .

Despite the fact that the intra-oral radiographs were standardized, some degree of magnification is inevitable, and therefore it must be emphasized that the measurements are approximated and not "real size." However, the computer-assisted analysis method was

associated with high reproducibility, since a high correlation was found between the first and second measurements.

This study introduced subtraction radiography as a new method for assessing morphologic changes and remodeling processes of extraction sites during the healing period. The image analysis demonstrated that a large amount of bone generation, bone loss as well as remodeling, takes place within 12 months after tooth extraction. Bone formation in the alveoli and loss of height of the alveolar bone crest occurred simultaneously during the first 3 months. Formation of bone continued during the next 3 months. From 6 to 12 months, some of this new bone underwent remodeling. Furthermore, the size of the loss was almost unchanged from 3 to 12 months. When studying the subtraction images, loss of crestal bone height mainly occurred within the first 3-month period after tooth extraction, while reorganization of lamina dura took place during the entire healing period.

The digital subtraction technique is associated with several problems that should be considered when interpreting the resulting images. In this study, 11 patients were excluded from the image analysis because of limitations of the technique. In three patients, it was not possible to define a sufficient number of reference points. Subtraction radiographs of eight patients were excluded from the statistical analysis because of poor agreement between presubtraction

evaluation of the radiographs and the resulting subtraction images. In some cases, this disagreement may have biologic explanations. In two of these cases, the maxillary sinus was superimposed on the extraction site, and changes of this anatomic structure might have interfered with the results. In other cases, the unexpected results of the subtraction procedure may be explained by problems with alignment of the radiographs because of differences in projection geometry.

For the subtraction procedure in this study, changes in bone density were defined as a divergence from the mean gray value of an area expected to be unchanged. The threshold value for this divergence was set to the mean gray value of the ROC $\pm 2 \times$ SD. This factor 2 is arbitrary, but was chosen after performing the subtraction procedure with different factors in 10% of the material. The "optimal" resulting image, an image with maximum detection of changes in the ROI and as small a change as possible in the image outside the ROI, could best be achieved by a factor of 2. Obviously, changes shown as red or blue areas might be a result of difference in physical noise of the images within the same patient rather than a biologic change in bone density. However, the noise in the images of the same patient differed only slightly. Another limitation of subtraction radiography is that the visualization depends on the buccooral width of the defect. For example, total bone fill with uniform density in a cone-shaped defect like an extraction socket may

be visualized only in the coronal part because the alveolus makes up a larger fraction of the total width of the alveolar bone in the coronal compared with the apical part.

Different methods have been employed in the present study to evaluate changes of the alveolar bone following tooth extraction. Strong agreement was found between the linear radiographic measurements and subtraction analysis when studying the bone changes of the alveolar crest. Subtraction radiography is a supplementary radiographic method for evaluation of crestal changes of the alveolar bone.

By means of linear radiographic measurements, a bone loss of less than 0.1 mm at the teeth adjacent to the extraction site was found. This does not contradict the finding that the attachment level was almost unchanged during the healing period. Finally, the model analysis revealing a loss of height of approximately 1 mm corresponded very well with the linear radiographic measurements.

The reduction of alveolar bone volume following tooth extraction may interfere with placement of implants and influence the treatment success of fixed or removable dentures with regard to function and esthetics. Therefore, it would be advantageous to avoid this loss of tissue. Procedures have been suggested to facilitate bone formation in extraction sockets and minimize loss of bone height and buccolingual width. Placement of grafting materials in extraction alveoli has been used with contradictory

results.²²⁻²⁴ Guided tissue regeneration, with or without grafting material, can be applied to preserve bone volume.^{11,25} Immediate implant placement in fresh extraction sockets has been shown to be a successful alternative to the original treatment protocol.²⁶⁻³⁰ In addition to the advantages of reduced treatment time and costs, preservation of the osseous structures could be provided by this concept.³¹⁻³⁴ However, in some cases, it is preferable to defer the time of implant placement, eg, to minimize the risk of complications caused by infected recipient sites. This study indicates that concerning the optimal dimensions of the alveolar bone, it would be favorable to place the implant as soon as possible following tooth extraction.

Because preservation of alveolar bone following tooth extraction has a major impact on the functional and esthetic outcome of subsequent prosthetic treatment, further research should be conducted on this topic.

Acknowledgments

The authors wish to thank the staff at the Department of Oral Radiology, and the Department of Periodontology & Oral Gerodontology, Royal Dental College, University of Aarhus, Denmark, for their assistance. In addition, we appreciate Torben Jørgensen's help with the program for digital subtraction radiography.

References

- Schneider R. Prosthetic concerns about atrophic alveolar ridges. *Postgrad Dent* 1999;6:3-7.
- Atwood DA, Coy WA. Clinical, cephalometric, and densitometric study of reduction of residual ridges. *J Prosthet Dent* 1971;26:280-295.
- Atwood DA. Reduction of residual ridges: A major oral disease entity. *J Prosthet Dent* 1971;26:266-279.
- Huebsch RF, Hansen LS. A histopathologic study of extraction wounds in dogs. *Oral Surg Oral Med Oral Pathol* 1969;28:187-196.
- Amler MH, Johnson PL, Salman I. Histological and histochemical investigation of human alveolar socket healing in undisturbed extraction wounds. *J Am Dent Assoc* 1960;61:46-48.
- Boyne PJ. Osseous repair of the postextraction alveolus in man. *Oral Surg Oral Med Oral Pathol* 1966;21:805-813.
- Carlsson GE, Bergman B, Hedegard B. Changes in contour of the maxillary alveolar process under immediate dentures. A longitudinal clinical and x-ray cephalometric study covering 5 years. *Acta Odontol Scand* 1967;25:45-75.
- Carlsson GE, Persson G. Morphologic changes of the mandible after extraction and wearing of dentures. A longitudinal, clinical, and x-ray cephalometric study covering 5 years. *Odontol Revy* 1967;18:27-54.
- Pietrokovski J, Massler M. Alveolar ridge resorption following tooth extraction. *J Prosthet Dent* 1967;17:21-27.
- Johnson K. A study of the dimensional changes occurring in the maxilla following tooth extraction. *Aust Dent J* 1969;14:241-244.
- Lekovic V, Kenney EB, Weinlaender M, et al. A bone regenerative approach to alveolar ridge maintenance following tooth extraction. Report of 10 cases. *J Periodontol* 1997;68:563-570.
- Lam RV. Contour changes of the alveolar processes following extractions. *J Prosthet Dent* 1960;10:25-32.

13. Lehmann TM, Gröndahl HG, Benn DK. Computer-based registration for digital subtraction in dental radiology. *Dentomaxillofac Radiol* 2000;29:323–346.
14. Christgau M, Hiller KA, Schmalz G, Kolbeck C, Wenzel A. Accuracy of quantitative digital subtraction radiography for determining changes in calcium mass in mandibular bone: An in vitro study. *J Periodontol* 1998;33:138–149.
15. Christgau M, Hiller KA, Schmalz G, Kolbeck C, Wenzel A. Quantitative digital subtraction radiography for the determination of small changes in bone thickness: An in vitro study. *Oral Surg Oral Med Oral Pathol Oral Radiol Endod* 1998;85:462–472.
16. Loftin R, Webber R, Horton R, Tyndall D, Moriarty J. Effect of projective aspects variations on estimates of changes in bone mass using digital subtraction radiography. *J Periodontol* 1998;33:352–358.
17. Jensen J, Kragsskov J, Wenzel A, Sindet-Pedersen S. In vitro analysis of the accuracy of subtraction radiography and computed tomography scanning for determination of bone graft volume. *J Oral Maxillofac Surg* 1998;56:743–748.
18. Sewerin I. Device for serial intraoral radiography with controlled projection angles. *Tandlaegebladet* 1990;94:613–617.
19. Gotfredsen E, Kragsskov J, Wenzel A. Development of a system for craniofacial analysis from monitor-displayed digital images. *Dentomaxillofac Radiol* 1999;28:123–126.
20. Wenzel A, Sewerin I. Sources of noise in digital subtraction radiography. *Oral Surg Oral Med Oral Pathol* 1991;71:503–508.
21. Johnson K. A study of the dimensional changes occurring in the maxilla following tooth extraction—Part 1. Normal healing. *Aust Dent J* 1963;8:428–433.
22. Olson RA, Roberts DL, Osbon DB. A comparative study of polylactic acid, Gelfoam, and Surgicel in healing extraction sites. *Oral Surg Oral Med Oral Pathol* 1982;53:441–449.
23. Gülaldi NC, Shahlafar J, Makhsoosi M, Caner B, Araz K, Erben G. Scintigraphic evaluation of healing response after heterograft usage for alveolar extraction cavity. *Oral Surg Oral Med Oral Pathol Oral Radiol Endod* 1998;85:520–525.
24. Artzi Z, Nemcovsky CE. The application of deproteinized bovine bone mineral for ridge preservation prior to implantation. Clinical and histological observations in a case report. *J Periodontol* 1998;69:1062–1067.
25. Nevins M, Mellonig JT. Enhancement of the damaged edentulous ridge to receive dental implants: A combination of allograft and the Gore-Tex membrane. *Int J Periodontics Restorative Dent* 1992;12:96–111.
26. Brånemark P-I. Introduction to osseointegration. In: Brånemark P-I, Zarb G, Albrektsson T (eds). *Tissue-Integrated Prostheses. Osseointegration in Clinical Dentistry*. Chicago: Quintessence, 1985: 11–76.
27. Becker BE, Becker W, Ricci A, Geurs N. A prospective clinical trial of endosseous screw-shaped implants placed at the time of tooth extraction without augmentation. *J Periodontol* 1998;69:920–926.
28. Brägger U, Hämmerle CH, Lang NP. Immediate transmucosal implants using the principle of guided tissue regeneration (II). A cross-sectional study comparing the clinical outcome 1 year after immediate to standard implant placement. *Clin Oral Implants Res* 1996;7:268–276.
29. Lang NP, Brägger U, Hämmerle CH, Sutter F. Immediate transmucosal implants using the principle of guided tissue regeneration. I. Rationale, clinical procedures and 30-month results. *Clin Oral Implants Res* 1994;5:154–163.
30. Schropp L, Kostopoulos L, Wenzel A. Bone healing following immediate versus delayed placement of titanium implants into extraction sockets—A prospective clinical study. *Int J Oral Maxillofac Implants* 2003;18:189–199.
31. Denissen HW, Kalk W. Preventive implantations. *Int Dent J* 1991;41:17–24.
32. Denissen HW, Kalk W, Veldhuis HA, van Waas MA. Anatomic considerations for preventive implantation. *Int J Oral Maxillofac Implants* 1993;8:191–196.
33. Kalk W, Denissen HW, Käyser AF. Preventive goals in oral implantology. *Int Dent J* 1993;43:483–491.
34. Wheeler SL, Vogel RE, Casellini R. Tissue preservation and maintenance of optimum esthetics: A clinical report. *Int J Oral Maxillofac Implants* 2000;15:265–271.