

# Surgical Treatment of Peri-implantitis

Søren Schou, DDS, Dr Odont, PhD<sup>1</sup>/Tord Berglundh, DDS, Odont Dr<sup>2</sup>/Niklaus P. Lang, DDS, MS, PhD<sup>3</sup>

*Surgical treatment of peri-implantitis lesions can be performed in cases with considerable pocket formation (larger than 5 mm) and bone loss after the acute infection has been resolved and proper oral hygiene has been instituted. A literature review was conducted to ascertain current knowledge about surgical treatment options for peri-implantitis around commercially pure titanium implants. Recently reported animal studies involving implants with a rough surface indicate that considerable bone regeneration and re-osseointegration can be obtained by using membrane-covered autogenous bone graft particles. However, comparisons of the treatment outcomes in studies involving humans and animals are difficult because of differences in implant type, graft type, and evaluation protocols. In addition, different treatment procedures, including implant surface decontamination methods, have been used. Therefore, further long-term studies in humans involving sufficient numbers of subjects are needed to provide a solid basis for recommendations regarding the surgical treatment of peri-implantitis. Moreover, the encouraging treatment outcomes of regenerative procedures recently revealed in animal experiments and applied in the treatment of peri-implantitis around implants with sandblasted/acid-etched surfaces have not yet been documented for implants with other surfaces, especially turned surfaces. Numerous implant surface decontamination methods have been suggested as part of the surgical treatment of peri-implantitis. Decontamination of affected implants with titanium plasma-sprayed or sandblasted/acid-etched surfaces may most easily and effectively be achieved by applying gauze soaked alternately in chlorhexidine and saline. INT J ORAL MAXILLOFAC IMPLANTS 2004;19(SUPPL):140-149*

**Key words:** dental implants, pathology, peri-implant infection, peri-implantitis, treatment

Various treatment modalities for plaque-induced inflammatory lesions in the peri-implant tissues have been described.<sup>1-4</sup> Thus, mechanical debridement, antiseptics, antibiotics, surgical procedures, and explantation were suggested to be used depending on the severity of the clinical and radiographic manifestations of the lesions.<sup>1,2</sup> The present review will focus on the current knowledge about surgical treatment options for peri-implantitis around commercially pure titanium implants. Single

case reports and studies involving titanium-alloy implants or hydroxyapatite-coated implants were not included in this review.

## SURGICAL PROCEDURES

Surgical treatment of peri-implantitis lesions may be performed in cases with considerable pocket formation (larger than 5 mm) and bone loss.<sup>1,2</sup> As clearly stated in the preceding review by Heitz-Mayfield and Lang,<sup>5</sup> prior to surgical therapy the acute infection must be resolved and proper oral hygiene instituted. The primary goals of the treatment are to eliminate the inflammatory lesion, stop the disease progression, and maintain the implant in function with healthy peri-implant tissues. Moreover, treatment procedures resulting in regeneration of the lost peri-implant tissues are desired.

## Animal Studies

Animal experiments evaluating procedures used for surgical treatment of peri-implantitis are reported in

<sup>1</sup>Consultant, Department of Oral and Maxillofacial Surgery, Aalborg University Hospital, Aalborg, Denmark.

<sup>2</sup>Professor and Chairman, Department of Periodontology, Sahlgrenska Academy at Göteborg University, Göteborg, Sweden.

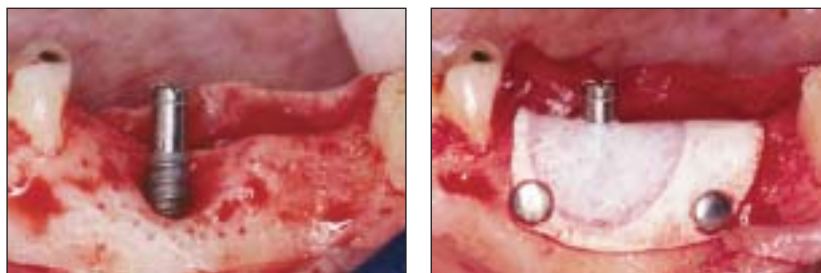
<sup>3</sup>Professor and Chairman, Department of Periodontology and Fixed Prosthodontics, School of Dental Medicine, University of Berne, Switzerland.

**Correspondence to:** Dr. Søren Schou, Department of Oral and Maxillofacial Surgery, Aalborg University Hospital, 18-22 Hobrovej, DK-9000 Aalborg, Denmark. Fax: +45-99-32-28-04. E-mail: ss@aas.nja.dk

**Figs 1a to 1d** Surgical treatment of experimentally induced peri-implantitis in a monkey model. From Schou et al<sup>20</sup>; reprinted with permission.

**Fig 1a** (Left) Elevation of a full mucoperiosteal flap, removal of granulation tissue, and preparation of multiple perforations of the cortical bone.

**Fig 1b** (Right) Affected area, after membrane placement over autogenous bone graft particles.



**Fig 1c** (Left) Subtraction image obtained 6 months after treatment with membrane-covered autogenous bone (white lines indicate the former border of the peri-implant defect).

**Fig 1d** (Right) Subtraction image 6 months after treatment with a conventional flap procedure.




Table 1.<sup>6-23</sup> Regenerative techniques, including barrier membranes alone and/or in combination with different bone substitutes, together with systemic antibiotic therapy, were evaluated in dogs and non-human primates. Implant type and surface, antibiotic therapy, surgical technique, implant surface decontamination, and healing conditions differed considerably among these studies. The evaluation included treatment modalities using both submerged and nonsubmerged approaches. Although clinically healthy peri-implant tissues were obtained and maintained in most of these studies, the amount of documented bone regeneration and re-osseointegration varied considerably. In many of these studies, the re-establishment of osseointegration has been questioned. It is unclear to what extent an implant surface previously exposed to plaque can obtain new bone-to-implant contact following decontamination. However, encouraging treatment outcomes have been reported from animal studies involving implants with rough surfaces.<sup>19-23</sup>

Surgical therapy aiming to regenerate the peri-implant bone using autogenous bone graft particles and expanded polytetrafluoroethylene (e-PTFE) membranes (Gore-Tex, Gore and Associates, Flagstaff, AZ) was recently evaluated.<sup>20,21</sup> Sixty-four ITI implants (Institut Straumann, Waldenburg, Switzerland) with a titanium plasma-sprayed (TPS) surface were placed in the jaws of 8 cynomolgus monkeys (*Macaca fascicularis*). Three months after implant placement, experimental peri-implantitis was created, resulting in bone loss of 4 to 6 mm.

Plaque control was then implemented and surgical therapy was carried out, including: (1) autogenous bone grafts covered by membranes, (2) autogenous bone grafts alone, (3) membranes alone, or (4) a control access flap procedure (Figs 1a and 1b). As part of the surgical procedure, the implant surface was cleaned alternately with 0.1% aqueous chlorhexidine and physiologic saline-soaked gauze. No attempts were made to cover the implants with oral mucosa as part of the surgical procedure.

The animals were sacrificed 6 months after surgical therapy. In cases where membrane-covered autogenous bone graft particles were used, bone gain was achieved corresponding to the level that existed before the peri-implant defects were established, as assessed by quantitative digital subtraction radiography. In contrast, defects treated with autogenous bone alone, membranes alone, or the control flap procedure yielded minimal bone regeneration (Figs 1c and 1d). Moreover, in defects treated with membrane-covered autogenous bone, stereologic estimates of ground sections demonstrated significantly larger amounts of bone regeneration and re-osseointegration than sections treated with the other 3 procedures (Figs 2a to 2c). When the treatment involved membrane-covered autogenous bone, a mean bone-to-implant contact of 45% was observed in the defect region. The corresponding estimates for autogenous bone grafting, membranes alone, and the control flaps were 22%, 21%, and 14%, respectively.

Other grafting materials, such as anorganic porous bovine bone mineral (Bio-Oss, Geistlich

**Table 1 Studies in Animals on Surgical Treatment Modalities for Peri-implantitis**

Study	Animals	Implants	Antibiotic	Treatment	Implant surface decontamination	Healing period	Results			Comments
							INF	R-Oss	BR	
Grunder et al 1993 <sup>6</sup>	10 dogs	40 Screw-Vent (AE)	NI	Flap surgery ± e-PTFE for 1 mo	Air-powder abrasive unit	Sub and NSub	No	≤ 0.3 mm groups	Minimal	Suspension membrane sutures used in the NSub group. High frequency of membrane exposures
Jovanović et al 1993 <sup>7</sup>	3 dogs	10 Brånemark (TS), 10 IMZ (TPS surface), and 10 Integral (HA-coated surface)	NI	1. Flap surgery and e-PTFE for 2 or 4.5 mo; 2. Flap surgery alone	Air-powder abrasive unit (30 s) and supersaturated citric acid (30 s)	Sub	NI	1. Limited; 2. Minimal	1. Yes; 2. Minimal	No comments
Ericsson et al 1996 <sup>8</sup>	5 dogs	10 Brånemark (TS)	Amoxicillin and metronidazole (3 wk)	1. Flap surgery; 2. No flap surgery	1. 1% delmopinol and abutments autoclaved; 2. No decontamination	Nsub	1. No; 2. Yes	1. No; 2. No	1. No; 2. No	No comments
Persson et al 1996 <sup>9</sup>	5 dogs	30 Brånemark (TS)	Amoxicillin and metronidazole (3 wk)	1. Flap surgery and e-PTFE for 4 mo; 2. No-flap surgery	1. 1% delmopinol; 2. No decontamination	1. Sub; 2. Nsub	1. No; 2. Yes	1. Minimal; 2. No	1. Minimal; 2. No	Vertical measurements of defect during surgery
Hürzeler et al 1997 <sup>10</sup>	7 dogs	42 Brånemark (TS)	Metronidazole (3 wk)	1. Flap surgery, HA, and e-PTFE for 4 mo; 2. Flap surgery, DFDB, and e-PTFE for 4 mo; 3. Flap surgery and HA; 4. Flap surgery and DFDB; 5. Flap surgery and e-PTFE for 4 mo; 6. Flap surgery alone	Air-powder abrasive unit (30 s)	Sub	No	1. 2.3 mm; 2. 2.2 mm; 3. 0.9 mm; 4. 0.9 mm; 5. 1.0 mm; 6. 0.3 mm	1. 2.4 mm; 2. 3.0 mm; 3. 1.3 mm; 4. 1.6 mm; 5. 2.5 mm; 6. 0.5 mm	No comments
Machado et al 1999 <sup>11</sup>	4 dogs	16 Napio (AE)	Metronidazole (3 wk)	1. Flap surgery, Bio-Oss, and PTFE for 4 mo; 2. Flap surgery and Bio-Oss; 3. Flap surgery and PTFE for 4 mo; 4. Flap surgery alone	Air-powder abrasive unit (30 s)	Sub	NI	NI	1. 1.6 mm; 2. 1.6 mm; 3. 1.4 mm; 4. 0.9 mm	Vertical measurements of defect during surgery
Persson et al 1999 <sup>12</sup>	4 dogs	24 Brånemark (TS)	Amoxicillin and metronidazole (3 wk)	Flap surgery	1. Rotating brush with pumice; 2. Cotton pellet soaked in saline	Sub	No	1. 0.4 mm; 2. 0.4 mm	Reference: Previous defect. 1. 2.0 mm <sup>2</sup> (59%); 2. 1.6 mm <sup>2</sup> (64%)	Fluorochrome injected 2 weeks after surgery

Table 1 Studies in Animals on Surgical Treatment Modalities for Peri-implantitis continued

Study	Animals	Implants	Antibiotic	Treatment	Implant surface decontamination	Healing period	Results			Comments
							INF	R-OSS	BR	
Weitzel et al 1999 <sup>3</sup>	7 dogs	39 ITI: 1. & 4. SLA surface, 2. & 5. TPS surface, 3. & 6. TS	Metronidazole (10 d)	1., 2., 3., Flap surgery and e-PTFE for 5.5 months; 4., 5., 6., Flap surgery alone	Copious CHX irrigation	Sub	No	Reference: Previous defect. 1. 20% (0.6 mm); 2. 14% (0.5 mm); 3. 2% (0.1 mm); 4. 11% (0.3 mm); 5. 14% (0.3 mm); 6. 7% (0.2 mm)	Reference: Previous defect. 1. 2.3 mm (83%); 2. 2.6 mm (73%); 3. 2.2 mm (62%); 4. 0.4 mm (15%); 5. 0.3 mm (14%); 6. 0.8 mm (31%)	Fluorochrome injected 2 weeks before surgery. Titanium ring placed around implant at defect bottom
Machado et al 2000 <sup>14</sup>	5 dogs	20 Napio (AE)	Metronidazole (3 wk)	1. Flap surgery, Bio-Oss, and PTFE for 4 mo; 2. Flap surgery and Bio-Oss; 3. Flap surgery and PTFE for 4 mo; 4. Flap surgery alone	Air-powder abrasive unit (30 s)	Sub	NI	Reference: 6 most coronal threads. 1. 27%; 2. 28%; 3. 31%; 4. 27%	Reference: 6 most coronal threads. 1. 52%; 2. 56%; 3. 52%; 4. 50%	No comments
Deppe et al 2001 <sup>15</sup>	6 dogs	60 Frialit-2 (TPS surface)	NI	1., 3., 5., Flap surgery alone; 2., 4., 6., Flap surgery and e-PTFE for 4 mo	1., 2., Air-powder abrasive unit (60 s); 3., 4. CO <sub>2</sub> laser (60 s); 5., 6., Air-powder abrasive unit (60 s) and CO <sub>2</sub> laser (60 s)	Sub	NI	Reference: 1. 0.8 mm; 2. 1.2 mm; 3. 1.0 mm; 4. 1.2 mm; 5. 0.8 mm; 6. 1.1 mm	Reference: No signs of thermal damage to surrounding bone after implant surface decontamination with CO <sub>2</sub> laser	
Nociti et al 2001 <sup>16,17</sup>	5 dogs	30 Napio (AE)	Metronidazole (3 wk)	Flap surgery alone or combined with Bio-Oss and PTFE for 4 mo; Bio-Oss and Bio-Gide membrane; PTFE for 4 mo; Bio-Oss; or Bio-Gide membrane	Air-powder abrasive unit (30 s)	Sub	NI	Reference: Previous defect; 26% to 31% irrespective of treatment	Reference: Previous vertical defect height. 14% to 28% irrespective of treatment	Vertical measurements of defect during surgery
Persson et al 2001 <sup>18</sup>	2 dogs	16 Brånemark (TS) modified implants versus standard implants	Amoxicillin and metronidazole (3 wk)	Flap surgery	Replacement of the coronal contaminated implant part with a non-contaminated part; versus cotton pellet soaked in saline	Sub	No	New osseointegration identified on the replaced implant part; versus minimal	Yes	Fluorochrome injected 2 wk after surgery
Persson et al 2001 <sup>19</sup>	4 dogs	24 ITI TS versus SLA surface	Amoxicillin and metronidazole (17 d)	Flap surgery	Cotton pellet soaked in saline	Sub initially, but all NSub after 1 mo	No	Reference: Previous defect. TS: 22% (0.4 mm); SLA: 84% (1.2 mm)	Reference: Previous defect. TS: 3.8 mm <sup>2</sup> (72%); SLA: 3.2 mm <sup>2</sup> (77%)	Fluorochrome injected 2 wk after surgery

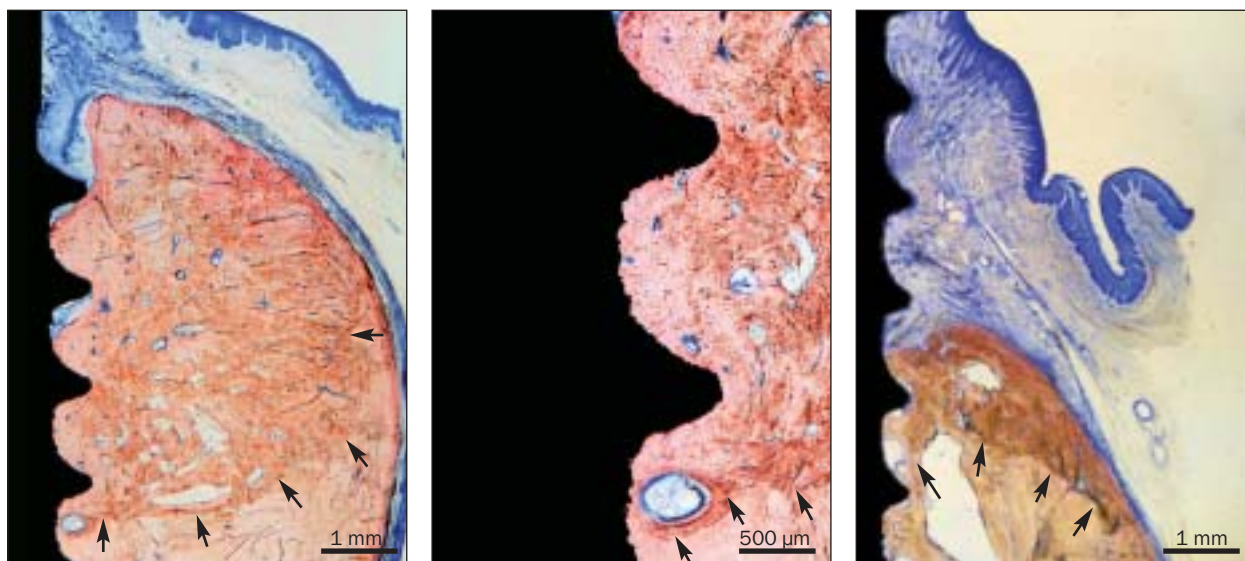
Table 1 Studies in Animals on Surgical Treatment Modalities for Peri-implantitis continued

Study	Animals	Implants	Antibiotic	Treatment	Implant surface decontamination	Healing period	INF	Results		
								R-OSS	BR	Comments
Schou et al 2003 <sup>50,21</sup>	8 monkeys	61 ITI (TPS surface)	Ampicillin and metronidazole (12 d)	1. Flap surgery, AB, and e-PTFE for 3 mo; 2. Flap surgery and AB; 3. Flap surgery and e-PTFE for 3 mo; 4. Flap surgery alone	Gauze soaked alternately in CHX and saline (5 min)	Nsub	No	Reference: Previous defect. 1. 45%; 2. 22%; 3. 21%; 4. 14%	Reference: Previous defect. 1. 16.1 mm <sup>2</sup> ; 4.7 mm (94%); 2. 9.2 mm <sup>2</sup> ; 4.0 mm (80%); 3. 6.3 mm <sup>2</sup> ; 3.0 mm (65%); 4. 5.4 mm <sup>2</sup> ; 1.9 mm (40%)	Transfer of defect border from radiographs to histologic sections. Unbiased stereologic estimates
Schou et al 2003 <sup>52</sup>	8 monkeys	62 ITI (TPS surface)	Ampicillin and metronidazole (12 d)	1. Flap surgery, Bio-Oss, and e-PTFE for 3 mo; 2. Flap surgery and Bio-Oss; 3. Flap surgery and e-PTFE for 3 mo; 4. Flap surgery alone	Gauze soaked alternately in CHX and saline (5 min)	Nsub	No	Reference: Previous defect. 1. 36%; 2. 16%; 3. 23%; 4. 13%	Reference: Previous defect. 1. 11.2 mm <sup>2</sup> ; 5.0 mm (111%); 2. 8.7 mm <sup>2</sup> ; 4.6 mm (96%); 3. 7.9 mm <sup>2</sup> ; 3.7 mm (74%); 4. 5.3 mm <sup>2</sup> ; 2.1 mm (47%)	Transfer of defect border from radiographs to histologic sections. Unbiased stereologic estimates
Schou et al 2003 <sup>53</sup>	8 monkeys	57 ITI (TPS surface)	Ampicillin and metronidazole (12 d)	Flap surgery, AB, and e-PTFE for 3 mo	1. Air-powder abrasive unit (5 min) and supersaturated citric acid (2 min); 2. Air-powder abrasive unit (5 min); 3. Gauze soaked in saline (5 min) and supersaturated citric acid (2 min); 4. Gauze soaked alternately in CHX and saline (5 min)	Nsub	No	Reference: Previous defect. 1. 46%; 2. 39%; 3. 43%; 4. 40%	Reference: Previous defect. 1. 14.1 mm <sup>2</sup> ; 4.6 mm (99%); 2. 14.1 mm <sup>2</sup> ; 4.7 mm (105%); 3. 14.2 mm <sup>2</sup> ; 4.4 mm (94%); 4. 13.9 mm <sup>2</sup> ; 4.7 mm (105%)	Transfer of defect border from radiographs to histological sections. Unbiased stereological estimates

All group values referred to are expressed as mean values.

AB = autogenous bone; AE = AE; BR = bone regeneration; CHX = chlorhexidine; DFDB = demineralized freeze-dried bone; e-PTFE = expanded polytetrafluoroethylene membrane; HA = hydroxyapatite; INF = inflammation; NI = no information; NSub = Nonsubmerged; PTFE = polytetrafluoroethylene membrane; R-Oss = re-osseointegration; SLA = sandblasted and acid-etched; Sub = submerged; TPS = titanium plasma-sprayed; TS = turned surface.

**Figs 2a to 2c** Treatment of experimentally created peri-implantitis defects in a monkey model. From Schou et al<sup>21</sup>; reprinted with permission.



**Fig 2a** Considerable bone regeneration occurred after surgical treatment involving autogenous bone graft particles and e-PTFE membrane (arrows indicate the former peri-implant defect border) (Stevenel's blue and alizarin red S).

**Fig 2b** Higher magnification. Considerable re-osseointegration was obtained.

**Fig 2c** Limited bone regeneration was achieved after treatment with a conventional flap procedure alone (Stevenel's blue and alizarin red S).

Pharma, Wolhusen, Switzerland) used alone or in combination with membranes, have also been evaluated in animal experiments (Table 1).<sup>11,14,16,17</sup> However, no statistically significant differences in bone regeneration were demonstrated between the evaluated procedures and the control flap procedure. Results from an animal study by Schou and coworkers using an experimental design similar to the one mentioned above<sup>20,21</sup> showed superior treatment outcomes with the combined use of Bio-Oss and e-PTFE membranes compared to Bio-Oss alone, membranes alone, or a control flap procedure.<sup>22</sup>

Considerable amounts of re-osseointegration to rough implant surfaces have also been demonstrated in dogs.<sup>19</sup> Twenty-four ITI implants with a turned or a sandblasted/acid-etched (SLA) surface were placed in 4 beagle dogs. Experimental peri-implantitis was induced over a period of 3 months until 50% of the initial bone support was lost. A surgical procedure, including cleaning of the implant surface with cotton pellets soaked in saline, was carried out following the administration of systemic antibiotics. The implants were initially submerged but became exposed to the oral environment after 1 month of healing. A histologic evaluation performed 6 months after treatment revealed comparable amounts of bone regeneration within the previous defects around implants with turned and SLA surfaces. In contrast, the amount of re-osseointegration was substantially greater on SLA

implant surfaces (84%) than on turned implant surfaces (22%). Therefore, it was suggested that re-osseointegration after treatment of the peri-implantitis defect appeared to be dependent on the surface characteristics of the implant. Similar findings were also evident in a previous animal study.<sup>13</sup>

In a study by Persson and associates<sup>19</sup> with an experimental design comparable to that mentioned above, new osseointegration was observed on experimental 2-part implants with a turned surface.<sup>18</sup> Surgical therapy and replacement of the coronal and previously contaminated part of the implant with a pristine implant unit resulted in new osseointegration. This observation indicated that the pristine turned implant surface exhibited different properties for osseointegration than a previously contaminated surface.

### Human Studies

Human studies have also focused on the regenerative potential of membranes, bone substitutes, and autogenous bone grafts in the surgical treatment of peri-implantitis (Table 2).<sup>24-28</sup> Additional systemic antibiotic therapy was included in most studies. Furthermore, the evaluations have included both submerged implants and implants penetrating the oral mucosa during the healing period. The animal studies mentioned above indicated that membrane-covered autogenous bone graft particles appeared

most effective in the surgical treatment of peri-implantitis around implants with a rough surface.

The use of autogenous bone grafts with or without membrane coverage in humans was also evaluated in 3 studies involving 90 implants (Table 2).<sup>26-28</sup> A clinically healthy peri-implant mucosa was a consistent finding after treatment, but the amount of bone regeneration varied widely among studies. As an example, 25 ITI implants with a TPS surface were analyzed in one study.<sup>26</sup> The surgical treatment involved placement of blocks or particles of autogenous bone without membrane coverage after cleaning of the implant surface with an air-powder abrasive unit. A mean radiographic bone gain of 4.2 mm, corresponding to 100% regeneration, was observed after 3 years. However, in another study that involved 24 IMZ implants (Friadent, Mannheim, Germany) with a TPS surface,<sup>27</sup> autogenous bone graft particles covered with an e-PTFE membrane were used after implant surface decontamination using photosensitization by Toluidine blue and soft laser irradiation. The radiographic evaluation performed after an observation period of about 9.5 months demonstrated a mean bone gain of 2 mm, corresponding to only 36% of the previous defect height. In contrast, the third study involved 41 IMZ and Friadent implants,<sup>28</sup> and 3 different surgical treatment procedures were performed: (1) autogenous bone covered with an e-PTFE membrane; (2) autogenous bone covered with a porcine-derived bilayered types I and III collagen membrane (Bio-Gide, Geistlich Pharma); or (3) autogenous bone without membrane coverage. The autogenous bone graft was used either as a block or as particles. The implant surface was cleaned with chlorhexidine, citric acid, and hydrogen peroxide. Bone gain varied between 1.9 and 2.8 mm after an observation period of 3 years. It was concluded that additional application of a membrane did not improve the treatment outcome in comparison to the use of autogenous bone alone. However, it should be noted that no randomization was performed, and hence the results of this study should be interpreted with care.

Membranes are applied to stabilize the blood clot and to prevent growth of connective tissue and epithelium into the peri-implant bone defect during surgical therapy.<sup>29,30</sup> Various grafting materials have been combined with membranes to maintain the space created under the membrane and to serve as an osteoconductive scaffold to promote bone regeneration. Findings from animal studies have indicated that the combination of grafting materials and a membrane is preferable in the surgical treatment of the osseous defects in peri-implantitis.<sup>20-22</sup> However, membrane exposure is a frequent complication after

such procedures. For example, 13% to 38% of the membranes were exposed in the previously mentioned experimental studies.<sup>20-22</sup> Exposure of porous e-PTFE membranes may result in bacterial penetration and lead to infection.<sup>31-33</sup> Although topical application of chlorhexidine seems to reduce plaque formation on the exposed membranes, bacterial penetration cannot be prevented.<sup>33</sup> Satisfactory results may occasionally be obtained despite membrane exposure if plaque control is optimal.<sup>29,30</sup> However, based upon observations in humans, immediate removal of exposed membranes used as a part of the surgical treatment of peri-implantitis is recommended to avoid impeding bone regeneration.<sup>27</sup> Future studies may shed more light on this issue.

### Conclusions Regarding Surgical Treatments

Surgical treatment of peri-implantitis seems feasible. Recently performed animal studies involving implants with a rough surface indicate that considerable bone regeneration and re-osseointegration can be obtained by using membrane-covered autogenous bone graft particles. Comparisons of the treatment outcomes in studies involving humans and animals are difficult because of differences in implant type, graft type, and evaluation protocols. In addition, different treatment procedures, including implant surface decontamination methods, have been used. Therefore, further long-term studies in humans involving sufficient numbers of subjects are needed to provide a solid basis for recommendations regarding the surgical treatment of peri-implantitis. It is important to underline that osseous defects of peri-implantitis normally exhibit well-demarcated craters. Peri-implant bone defects with horizontal bone loss or craters with a narrow crestal opening may be more difficult to access for regenerative procedures. Finally, the encouraging treatment outcomes of regenerative procedures recently revealed in animal experiments and applied in the treatment of peri-implantitis around implants with a SLA surface have not yet been documented for implants with other surfaces, especially turned surfaces.

### IMPLANT SURFACE DECONTAMINATION

It has been suggested that the establishment of an implant surface conducive to bone formation is a prerequisite for successful regenerative treatment of peri-implantitis.<sup>34</sup> Contaminants such as bacteria and their products, calculus, and soft tissue cells should be removed without modifying the implant surface. However, it is still unknown to what extent these contaminants have to be removed to achieve a successful treatment outcome.<sup>35</sup>

Table 2 Studies in Humans on Surgical Treatment Modalities for Peri-implantitis

Study	No. of patients	Implants and time since placement	Antibiotic	Treatment	Implant surface decontamination	Healing period	Observation period	Results		
								Inflammation	"Bone" regeneration	
Hämmerle et al 1995 <sup>24</sup>	2	2 ITI (TPS surface); 4 y	1. Metronidazole and amoxicillin (10 d); 2. Amoxicillin (10 d)	Flap surgery and e-PTFE	Irrigation alternately with CHX and saline	NSub	1 y	1. No. PD: 3.3 mm; 2. No. PD: 3.7 mm	1. 2.7 mm; 2. 1.9 mm	1. Membrane removal after 4-5 mo; 2. Membrane removal after 6.5 mo
Mellonig et al 1995 <sup>25</sup>	3	3 titanium hollow cylinders (TPS surface); 1.5 to 2.5 y	NI	Flap surgery, HA or DFDB soaked in tetracycline, and e-PTFE	Tetracycline irrigation	NSub	8 to 12 mo	No	Yes	Membrane removal after 6 to 9 wk
Behneke et al 2000 <sup>26</sup>	17	25 ITI (TPS surface); 8 implants within 2 y of function, 17 implants after 2 y of function	Metronidazole (7 d)	Flap surgery and AB (block or particulate) fixated with screws or fibrin glue	Air-powder abrasive unit (30 s)	NSub	6 to 36 mo	No. PD after 3 y: 1.6 mm	After 3 y: 4.2 mm (100%)	Yes
Haas et al 2000 <sup>27</sup>	17	24 IMZ (TPS surface)	Penicillin (5 d)	Flap surgery, AB, and e-PTFE	Photosensitization by Toluidine blue and soft laser irradiation	Sub	9.5 mo	No	2.0 mm (36%)	All membranes exposed
Khoury et al 2001 <sup>28</sup>	25	41 IMZ and Friadent; 5.8 y of function	According to antimicrobial susceptibility test (2 wk)	1. Flap surgery, AB (block or particulate), and e-PTFE; 2. Flap surgery, AB (block or particulate), and Bio-Gide membrane; 3. Flap surgery and AB (block or particulate)	CHX irrigation, citric acid, and H <sub>2</sub> O <sub>2</sub>	Sub	3 y	1. PD 2.8 mm; 2. PD 5.1 mm; 3. PD 2.9 mm	1. 2.8 mm; 2. 1.9 mm; 3. 2.4 mm	Membrane removal after 6 mo. 1. 45% of membranes exposed; 2. 33% of membranes exposed; 3. No complications

All group values referred to are expressed as mean values.

AB = autogenous bone; BR = "bone" regeneration; CHX = chlorhexidine; DFDB = demineralized freeze-dried bone; e-PTFE = expanded polytetrafluoroethylene membrane; HA = hydroxyapatite; INF = inflammation; NI = no information; NSub = nonsubmerged; OP = observation period; PD = probing depth; Sub = submerged; TPS = titanium plasma-sprayed.

Numerous implant surface decontamination methods have been suggested, either alone or in various combinations, as part of the surgical treatment of peri-implantitis both in animals and in humans (Tables 1 and 2).<sup>4</sup> In vitro studies focusing on various methods to clean the implant surface have recently been reviewed and discussed in detail.<sup>23</sup> It was concluded that several methods are inappropriate for implant surface cleaning, especially metal curettes for hand scaling, conventional sonic/ultrasonic scalers, and some types of lasers, which may severely damage the implant surface. Although implant surface damage can almost be prevented by using either ultrasonic scalers with a nonmetallic tip or resin/carbon fiber curettes, presence of implant threads and/or implant surface roughness may compromise the access for cleaning.

Animal models of experimental peri-implantitis have been useful for evaluation of various implant surface decontamination methods in the surgical treatment of peri-implantitis (Table 1).<sup>12,15,23</sup> No difference could be demonstrated regarding the degree of osseointegration with implants that were cleaned either with cotton pellets soaked in saline or with a rotating brush with pumice during regenerative surgery.<sup>12</sup> Furthermore, no difference could be detected when decontamination by a carbon dioxide laser and/or an air-powder abrasive unit was done during flap surgery with or without coverage of the defect by an e-PTFE membrane.<sup>15</sup>

Air-powder abrasive units are often recommended for the surgical treatment of peri-implantitis (Tables 1 and 2). The influence of various air-powder abrasive systems on the titanium surface has been evaluated in vitro and was previously reviewed.<sup>23</sup> Although increased implant surface roughness and retained powder particles have been observed as a result of such application, no or only minor surface changes were identified in most studies. The mixture of water and abrasive powder is driven by compressed air. Therefore, the pressure applied may cause complications. However, the number of reported emphysema and pneumoparotitis cases induced by air-powder abrasive units appears to be low.<sup>36-38</sup>

Recently, 4 implant surface decontamination methods were compared in a monkey model: (1) air-powder abrasive technique followed by citric acid application, (2) air-powder abrasive technique, (3) gauze soaked in saline followed by citric acid application, and (4) gauze soaked alternately in 0.1% chlorhexidine and saline.<sup>23</sup> Experimental peri-implant defects, created over a period of 9 to 17 months around implants with a TPS surface, were surgically exposed. Each implant surface was subjected to one of the previously mentioned treatment

procedures. All defects were filled with autogenous bone graft particles and covered by an e-PTFE membrane. Clinical parameters, radiography (including quantitative digital subtraction radiography), histology, and stereology did not reveal significant differences between any of the methods used. Almost complete bone fill and considerable reosseointegration were obtained irrespective of the method applied. Hence, it was concluded that for implants with a rough surface, the simplest method, ie, gauze soaked alternately in chlorhexidine and saline, should be the preferred implant surface decontamination method when combined with membrane-covered autogenous bone graft particles.

Findings from an in vitro study combining photosensitization by Toluidine blue solution and soft laser irradiation have indicated that elimination of bacteria from different titanium surfaces without modification of the implant surface was possible.<sup>39</sup> A clinical and microbiologic study confirmed that this technique also significantly reduced the number of bacteria on a TPS surface.<sup>40</sup> The method was applied to 24 implants with a TPS surface in humans in combination with membrane-covered autogenous bone grafts.<sup>27</sup> Bone regeneration was obtained, but the procedure was not compared to other methods or controls.

### Conclusions Regarding Implant Decontamination

Decontamination of peri-implantitis-affected implants may be achieved most easily and effectively by applying gauze soaked alternately in chlorhexidine and saline, especially with implants with TPS or SLA surfaces that are undergoing surgical treatment.

### REFERENCES

1. Mombelli A, Lang NP. The diagnosis and treatment of peri-implantitis. *Periodontol* 2000 1998;17:63-76.
2. Mombelli A. Prevention and therapy of peri-implant infections. In: Lang NP, Karring T, Lindhe J (eds). *Proceedings of the 3rd European Workshop on Periodontology. Implant Dentistry*. Berlin: Quintessenz, 1999:281-303.
3. Baron M, Haas R, Dörtbudak O, Watzek G. Experimentally induced peri-implantitis: A review of different treatment methods described in the literature. *Int J Oral Maxillofac Implants* 2000;15:533-544.
4. Klinge B, Gustafsson A, Berglundh T. A systematic review of the effect of anti-infective therapy in the treatment of peri-implantitis. *J Clin Periodontol* 2002;29(suppl):213-225.
5. Heitz-Mayfield LJA, Lang NP. Antimicrobial treatment of peri-implant diseases. *Int J Oral Maxillofac Implants* 2004; 19(suppl):128-139.
6. Grunder U, Hürzeler MB, Schüpbach P, Strub JR. Treatment of ligature-induced peri-implantitis using guided tissue regeneration: A clinical and histologic study in the beagle dog. *Int J Oral Maxillofac Implants* 1993;8:282-293.

7. Jovanovic SA, Kenney EB, Carranza FA, Donath K. The regenerative potential of plaque-induced peri-implant bone defects treated by a submerged membrane technique: An experimental study. *Int J Oral Maxillofac Implants* 1993;8:13–18.
8. Ericsson I, Persson LG, Berglundh T, Edlund T, Lindhe J. The effect of antimicrobial therapy on periimplantitis lesions. An experimental study in the dog. *Clin Oral Implants Res* 1996;7:320–328.
9. Persson LG, Ericsson I, Berglundh T, Lindhe J. Guided bone regeneration in the treatment of periimplantitis. *Clin Oral Implants Res* 1996;7:366–372.
10. Hürzeler MB, Quiñones CR, Schüpback P, Morrison EC, Caffesse RG. Treatment of peri-implantitis using guided bone regeneration and bone grafts, alone or in combination, in beagle dogs. Part 2: Histologic findings. *Int J Oral Maxillofac Implants* 1997;12:168–175.
11. Machado MAN, Stefani CM, Sallum EA, Sallum AW, Tramontina VA, Nociti FH Jr. Treatment of ligature-induced peri-implantitis defects by regenerative procedures: A clinical study in dogs. *J Oral Sci* 1999;41:181–185.
12. Persson LG, Araújo MG, Berglundh T, Gröndahl K, Lindhe J. Resolution of peri-implantitis following treatment. An experimental study in the dog. *Clin Oral Implants Res* 1999;10:195–203.
13. Wetzel AC, Vlassis J, Caffesse RG, Hämmerle CHF, Lang NP. Attempts to obtain re-osseointegration following experimental peri-implantitis in dogs. *Clin Oral Implants Res* 1999;10:111–119.
14. Machado MAN, Stefani CM, Sallum EA, et al. Treatment of ligature-induced peri-implantitis defects by regenerative procedures. Part II: A histometric study in dogs. *J Oral Sci* 2000;42:163–168.
15. Deppe H, Horch H-H, Henke J, Donath K. Peri-implant care of ailing implants with the carbon dioxide laser. *Int J Oral Maxillofac Implants* 2001;16:659–667.
16. Nociti FH Jr, Machado MÂN, Stefani CM, Sallum EA, Sallum AW. Absorbable versus nonabsorbable membranes and bone grafts in the treatment of ligature-induced peri-implantitis defects in dogs. Part I. A clinical investigation. *Clin Oral Implants Res* 2001;12:115–120.
17. Nociti FH Jr, Machado MÂN, Stefani CM, Sallum EA. Absorbable versus nonabsorbable membranes and bone grafts in the treatment of ligature-induced peri-implantitis defects in dogs: A histometric investigation. *Int J Oral Maxillofac Implants* 2001;16:646–652.
18. Persson LG, Ericsson I, Berglundh T, Lindhe J. Osseointegration following treatment of peri-implantitis and replacement of implant components. An experimental study in the dog. *J Clin Periodontol* 2001;28:258–263.
19. Persson LG, Berglundh T, Sennerby L, Lindhe J. Re-osseointegration after treatment of peri-implantitis at different implant surfaces. An experimental study in the dog. *Clin Oral Implants Res* 2001;12:595–603.
20. Schou S, Holmstrup P, Jørgensen T, Stoltze K, Hjørtting-Hansen E, Wenzel A. Autogenous bone graft and ePTFE membrane in the treatment of peri-implantitis. I. Clinical and radiographic observations in cynomolgus monkeys. *Clin Oral Implants Res* 2003;14:391–403.
21. Schou S, Holmstrup P, Skovgaard LT, Stoltze K, Hjørtting-Hansen E, Gundersen HJG. Autogenous bone graft and ePTFE membrane in the treatment of peri-implantitis. II. Stereologic and histologic observations in cynomolgus monkeys. *Clin Oral Implants Res* 2003;14:404–411.
22. Schou S, Holmstrup P, Jørgensen T, et al. Anorganic porous bovine-derived bone mineral (Bio-Oss) and ePTFE membrane in the treatment of peri-implantitis in cynomolgus monkeys. *Clin Oral Implants Res* 2003;14:535–547.
23. Schou S, Holmstrup P, Jørgensen T, et al. Implant surface preparation in the surgical treatment of experimental peri-implantitis with autogenous bone graft and ePTFE membrane in cynomolgus monkeys. *Clin Oral Implants Res* 2003;14:412–422.
24. Hämmerle CHF, Fourmouis I, Winkler JR, Weigel C, Brägger U, Lang NP. Successful bone fill in late periimplant defects using guided tissue regeneration. A short communication. *J Periodontol* 1995;66:303–308.
25. Mellonig JT, Griffiths G, Mathys E, Spitznagel J. Treatment of the failing implant: Case reports. *Int J Periodontics Restorative Dent* 1995;15:385–395.
26. Behneke A, Behneke N, d'Hoedt B. Treatment of peri-implantitis defects with autogenous bone grafts: Six-month to 3-year results of a prospective study in 17 patients. *Int J Oral Maxillofac Implants* 2000;15:125–138.
27. Haas R, Baron M, Dörtbudak O, Watzek G. Lethal photosensitization, autogenous bone, and e-PTFE membrane for the treatment of peri-implantitis: Preliminary results. *Int J Oral Maxillofac Implants* 2000;15:374–382.
28. Khoury F, Buchmann R. Surgical therapy of peri-implant disease: A 3-year follow-up study of cases treated with 3 different techniques of bone regeneration. *J Periodontol* 2001;72:1498–1508.
29. Hämmerle CHF, Karring T. Guided bone regeneration at oral implant sites. *Periodontol* 2000 1998;17:151–175.
30. Hämmerle CHF. Membranes and bone substitutes in guided bone regeneration. In: Lang NP, Karring T, Lindhe J (eds). *Proceedings of the 3rd European Workshop on Periodontology. Implant Dentistry*. Berlin: Quintessence, 1999: 468–499.
31. Simion M, Baldoni M, Rossi P, Zaffe D. A comparative study of the effectiveness of e-PTFE membranes with and without early exposure during the healing period. *Int J Periodontics Restorative Dent* 1994;14:167–180.
32. Nowzari H, Slots J. Microbiologic and clinical study of polytetrafluoroethylene membranes for guided bone regeneration around implants. *Int J Oral Maxillofac Implants* 1995;10:67–73.
33. Simion M, Trisi P, Maglione M, Piattelli A. Bacterial penetration in vitro through GTAM membrane with and without topical chlorhexidine application. A light and scanning electron microscopic study. *J Clin Periodontol* 1995;22:321–331.
34. Schwartz Z, Kieswetter K, Dean DD, Boyan BD. Underlying mechanisms at the bone-surface interface during regeneration. *J Periodontol Res* 1997;32:166–171.
35. Mombelli A. Microbiology and antimicrobial therapy of peri-implantitis. *Periodontol* 2000 2002;28:177–189.
36. Brown FH, Ogletree RC, Houston GD. Pneumoparotitis associated with the use of an air-powder prophylaxis unit. *J Periodontol* 1992;63:642–644.
37. Finlayson RS, Stevens FD. Subcutaneous facial emphysema secondary to use of the Cavi-Jet. *J Periodontol* 1988;59: 315–317.
38. Bergendal T, Forsgren L, Kvint S, Löwstedt E. The effect of an air-abrasive instrument on soft and hard tissues around osseointegrated implants. A case report. *Swed Dent J* 1990; 14:219–223.
39. Haas R, Dörtbudak O, Mensdorff-Pouilly N, Mailath G. Elimination of bacteria on different implant surfaces through photosensitization and soft laser. An in vitro study. *Clin Oral Implants Res* 1997;8:249–254.
40. Dörtbudak O, Haas R, Bernhart T, Mailath-Pokorny G. Lethal photosensitization for decontamination of implant surfaces in the treatment of peri-implantitis. *Clin Oral Implants Res* 2001;12:104–108.