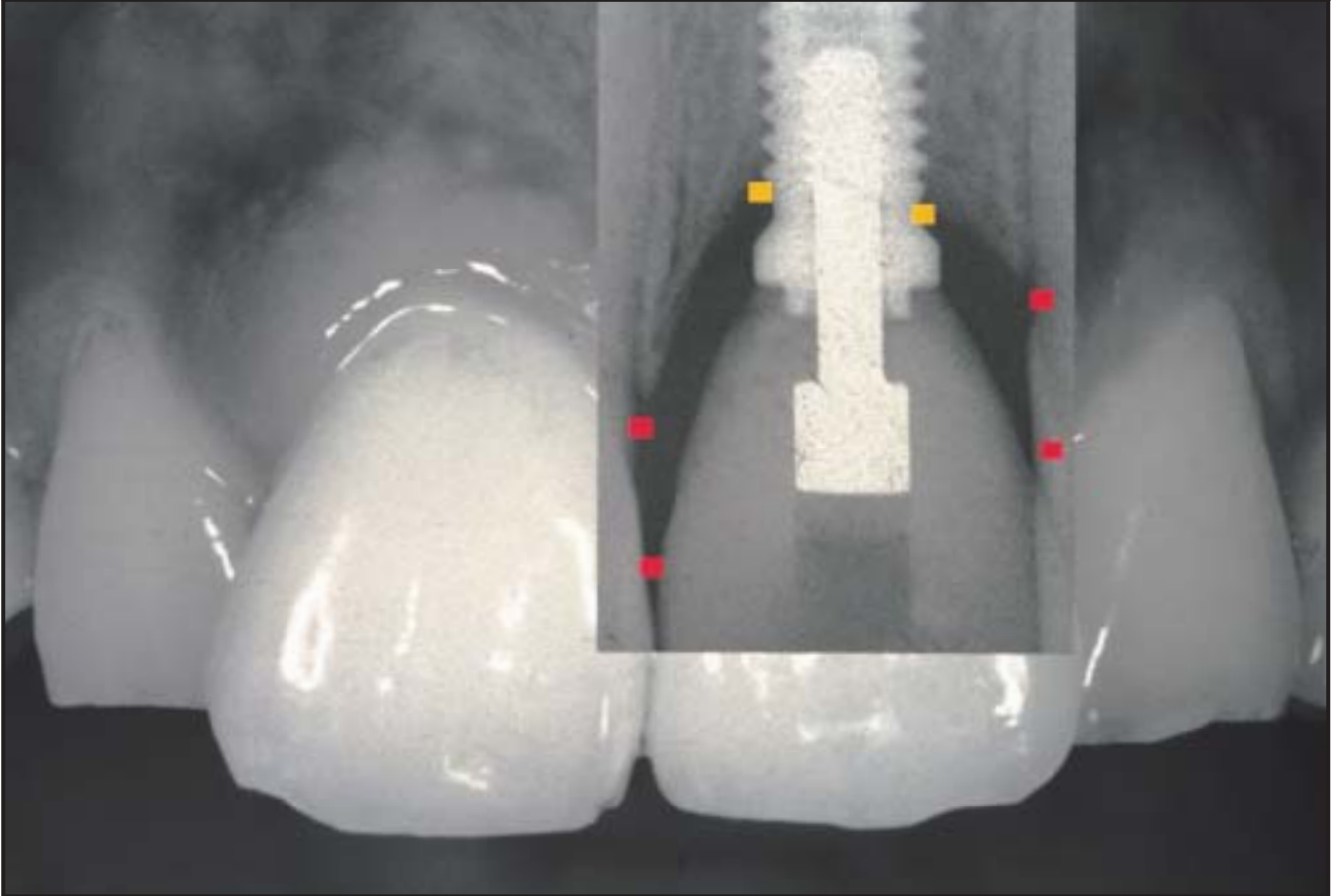
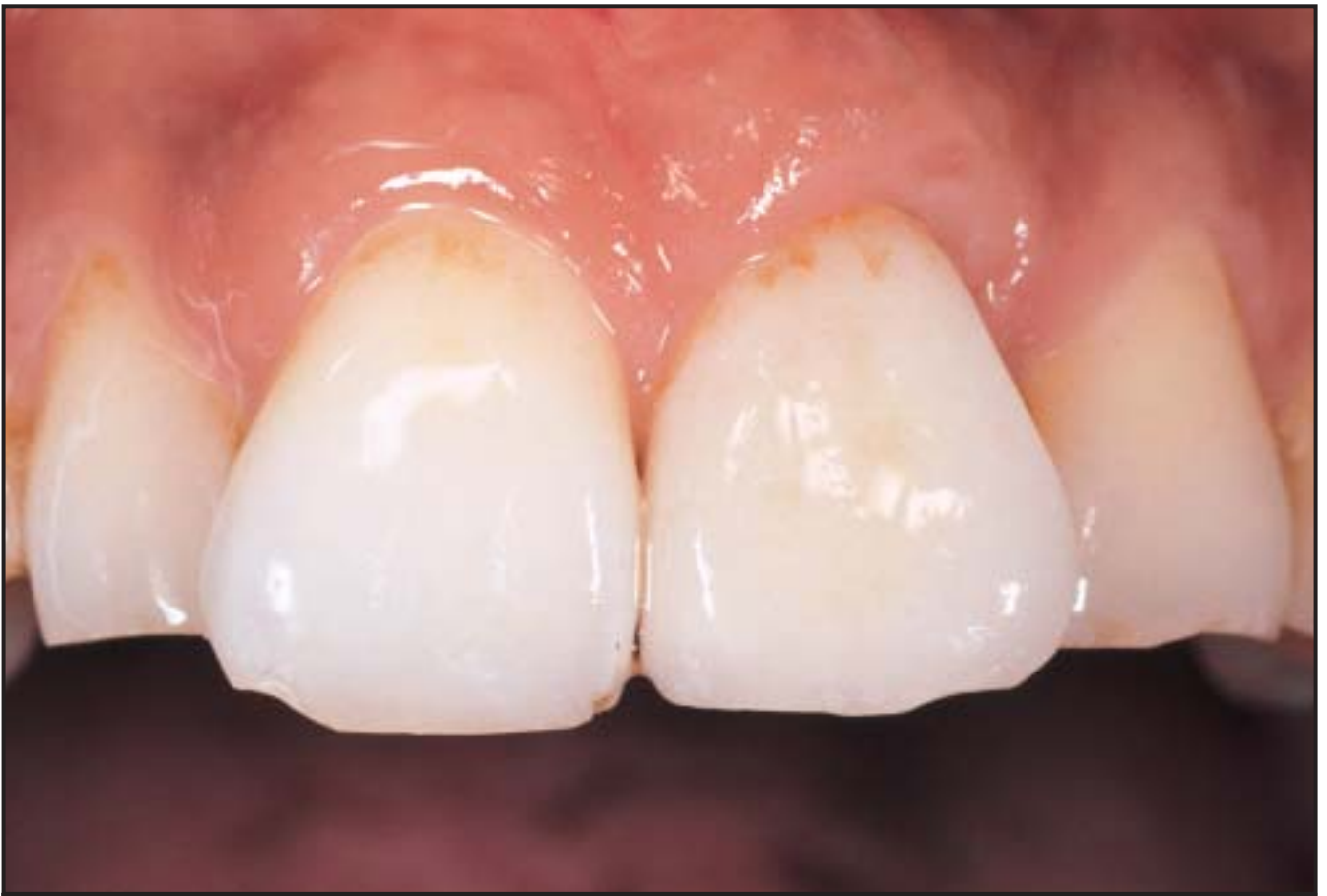
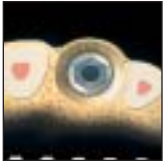Influence of the 3-D Bone-to-Implant Relationship on Esthetics



Ueli Grunder, DMD*
Stefano Gracis, DMD**
Matteo Capelli, DMD**

There are biologic limits of the soft tissue dimension around implants; therefore, the limiting factor for the esthetic result of implant therapy is the bone level at the implant site. Clinicians must focus on the 3-D bone-to-implant relationship to establish the basis for an ideal and harmonic soft tissue situation that is stable over a long period. In some situations, missing bone is a limiting factor for esthetics; in others, it is possible to regenerate new bone around implants. As a certain amount of bone resorption occurs around implants as soon as the implant is in contact with the oral environment, the distance between an implant and adjacent tooth, as well as the distance between two implants, is as important as the bone volume on the buccal side of the implant head and in the papillary area, especially for the long-term result. This article discusses the 3-D bone-to-implant relationship and its influence on soft tissue esthetics around implants. (Int J Periodontics Restorative Dent 2005;25:113–119.)

*Private Practice, Zollikon-Zürich, Switzerland.

**Private Practice, Milan, Italy.

Correspondence to: Dr Ueli Grunder, Dufourstrasse 7a, Zollikon-Zürich 8702, Switzerland.

To achieve an ideal esthetic result with implants, many parameters are of importance. The correct positioning of the implant is one of the key factors, together with the establishment of the optimum volume of hard and soft tissues. The optimal implant position is in the center of the tooth to be replaced, 1.5 to 2.0 mm more palatal than the expected buccal emergence profile at the gingival margin of the crown. What is more difficult to define is the ideal hard and soft tissue volume around the implant head that can guarantee the presence of an interproximal papilla and an esthetically stable mucosal margin over time.

The natural thickness of the connective tissue overlying the bone around implants (buccal side) is within a narrow range between 2.8 and 3.8 mm.^{1–5} The height of the interproximal soft tissues between natural teeth, as well as between a natural tooth and an implant, ranges from 3.5 to 5.0 mm.^{6–9} The soft tissue dimension between implants is not known from the scientific point of view, but it seems to be similar.

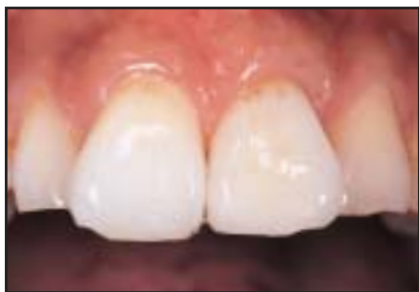

Fig 1a (left) Clinical appearance of papillae next to ideally placed single implant.

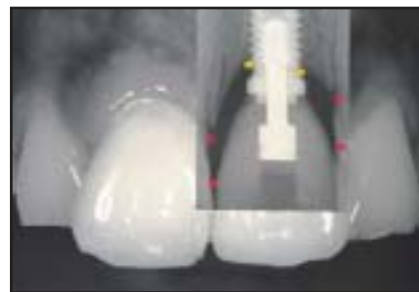

Fig 1b (right) Superimposed radiographic and clinical images of the same restoration demonstrate that the papilla is mainly determined by bone attachment on tooth side.

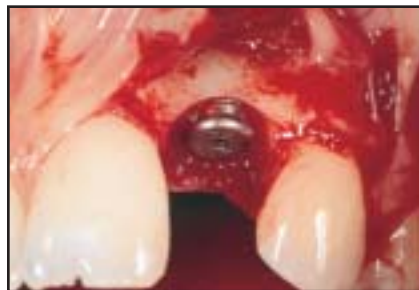

Fig 2a Circumferential crater around implant head demonstrates the formation of horizontal biologic width after 2 years of loading.

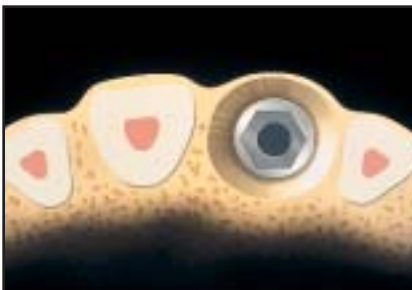
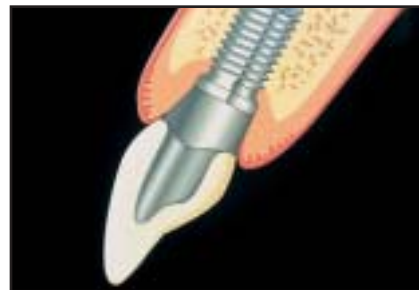
Fig 2b Thickness that bone on buccal side of implant should have to support gingival margin despite horizontal crater formation.



The presence of bone is the first determining factor for the soft tissue contour. Therefore, clinicians clearly have to focus their interest on the volume of bone to achieve ideal esthetic results.

The presence of a papilla depends on the following factors: the level of the bone, volume of the connective tissue, and proximal support of the crowns. When one considers the situation of an implant next to a tooth, the presence of the papilla is mainly determined by the bone attachment on the tooth side^{8,10} (Fig 1), whereas the presence of a papilla between two implants depends on the amount of existing bone in the interproximal area. If there is sufficient soft tissue volume, its height

can be increased by applying pressure interproximally,¹¹ but only minor improvements can be expected.

In this context, it is important to take into consideration that a certain amount of bone resorption occurs around implants as soon as the implant is in contact with the oral environment. On average, the first bone-to-implant contact is about 1.5 to 2.0 mm below the implant shoulder¹² shortly after implant exposure. This bone resorption occurs not only in a vertical but also in a horizontal direction (Fig 2), as pointed out by Tarnow et al.¹³ The mean horizontal bone loss is 1.3 to 1.4 mm. With this knowledge in mind, the ideal three-dimensional implant-to-bone relationship can be described.

Single-tooth implant

Single tooth: Mesiodistal view

Because of the horizontal bone loss described above, the distance between an implant and a tooth should not be less than 1.5 mm. If this minimum distance is not maintained, the attachment on the tooth side will undergo resorption; this will, in turn, cause a reduction or loss of the interproximal papilla.¹⁴ The more apical the implant is placed, the bigger the distance between the implant and tooth has to be because of the triangular shape of the bone loss.

Single tooth: Buccolingual view

The 1.5-mm-wide crater will also appear on the buccal side of the implant head. Therefore, to avoid losing bone height, the bone thickness should be at least 2 mm, preferably 4 mm.¹⁵ If this amount of bone is not available, part of the buccal bone plate will be lost after remodeling, with the consequence of a high risk of soft tissue recession. Such a large amount of bone on the buccal side of the implant head does not exist normally and has to be created with augmentation procedures in almost every esthetically demanding case (Fig 3). This means that, even if an implant is placed into the existing bone without leaving any threads exposed, bone augmentation will still be needed.

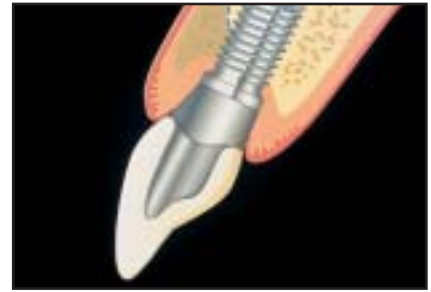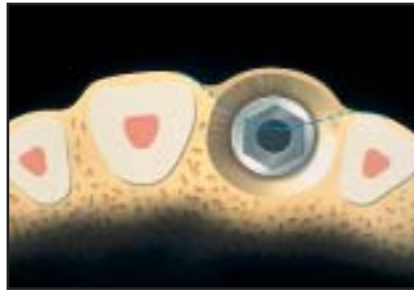


Fig 3a Ideal amount of bone needed to accommodate circumferential crater without loss of height in buccal mucosal margin; dotted line = original degree of buccolingual resorption of edentulous crest prior to bone augmentation.

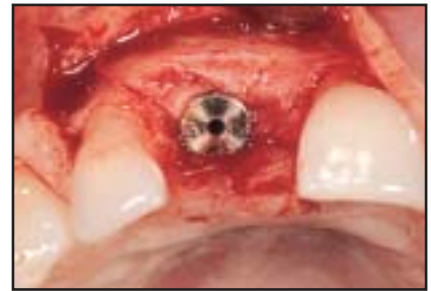
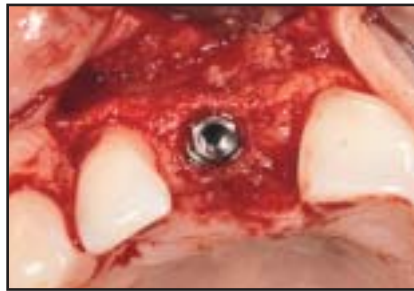
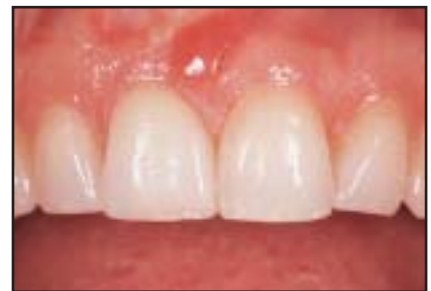Fig 3b Original buccal bone profile at time of implant placement (left) and time of implant exposure (right) as a result of bone augmentation procedure carried out at stage-one surgery.

Two adjacent implants

Adjacent implants: Mesiodistal view

If the distance between two implants is less than 3 mm, the interproximal bone level is expected to be more apical than the implant shoulder and therefore exhibit a reduced or nonexistent papilla. A distance of 3 mm between two implants will result in an interproximal bone height at most at the level of the implant shoulder. This situation (especially in highly scalloped cases) will still result in a deficit of the papilla because, in such cases, the implant shoulder is usually positioned more apical than the bone attachment of

Fig 3c Clinical appearance of restored implant in right central incisor position 2 years after exposure.



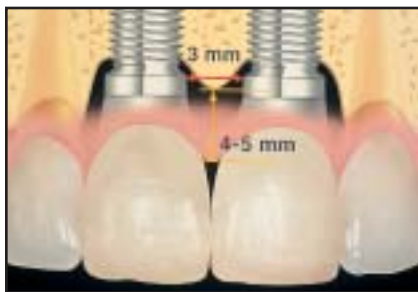

Fig 4a If the distance between two implants is only 3 mm, the interproximal bone level expected cannot be more coronal than the implant shoulder. Therefore, even in this situation, papilla will be reduced in height.

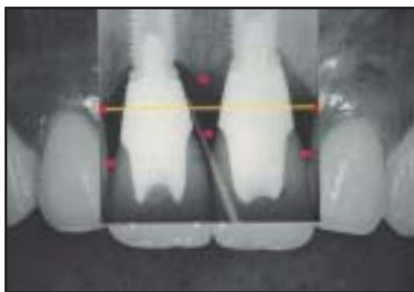
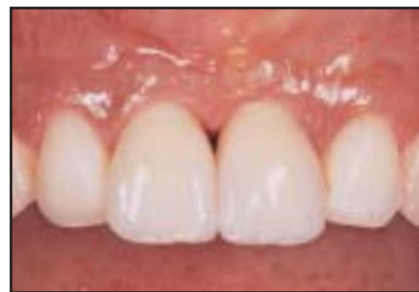
Fig 4b Radiographic (left) and clinical appearance (right) of completed restorations 1 year after implant exposure.



the adjacent teeth (Fig 4). Only if the implant-to-implant distance is greater than 3 mm can the interproximal bone peak be maintained above the implant shoulder. The more apical the implants are placed, the greater the implant-to-implant distance has to be because of the triangular shape of the bone loss. Unfortunately, it is often not possible to establish the required distance between two implants in the esthetic zone because of lack of space. Sufficient bone volume on the buccal side in the papillary area can help in such a situation, as described below.

Adjacent implants: Bucco-lingual view

On the buccal side of the implants, as described for single-tooth replacement, a bone thickness of 2 mm, preferably 4 mm, is required. This is the necessary prerequisite to maintain the peri-implant mucosal margin in a stable manner over time. In cases where the interimplant distance cannot be established as required, however, the interproximal papilla may not have a bone peak to support its buccal portion, as described above. A way to compensate for the lack of interproximal

bone caused by the reduced distance between two implants is to add an extra volume of bone on the buccal side of the papillary area. This extra bone volume can maintain and support the interproximal soft tissue over a long period (Fig 5).

Possible implant-abutment design improvements

In view of the situations described above, it is desirable to avoid the vertical and horizontal bone resorption. There are two possible solutions under investigation.

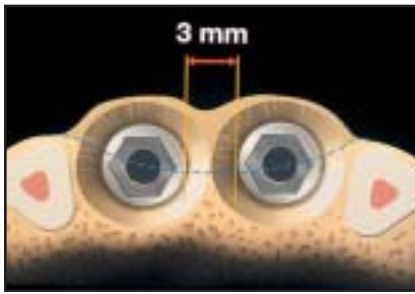


Fig 5a When the distance between two adjacent implants is 3 mm or less, it is important to have proper thickness of bone on buccal side of interproximal peak; dotted line = original degree of buccolingual resorption of edentulous crest prior to bone augmentation.

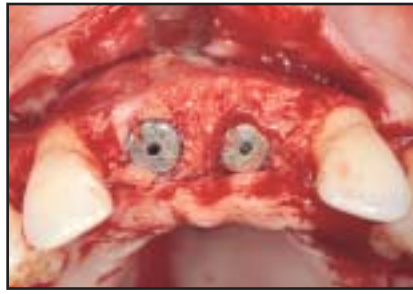

Fig 5b Distance between two 4-mm-diameter implants is about 3 mm, not enough to guarantee the presence of proper soft tissue papilla. Guided bone regeneration technique has been used to augment thickness of buccal bone across entire crest.

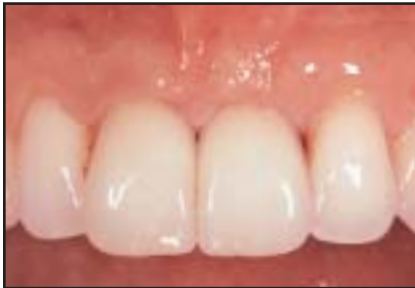

Fig 5c Clinical appearance of completed restorations 1 year after implant exposure.

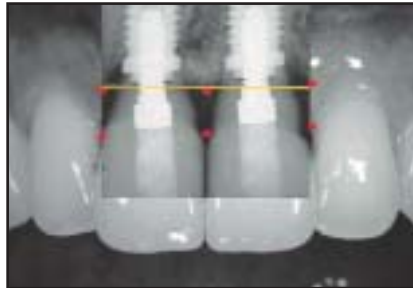
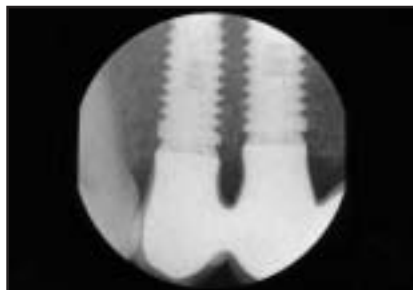
Fig 5d Superimposed radiographic and clinical images demonstrate relationship between bone and soft tissues and the presence of bone peak coronal to implants' shoulders despite the interimplant distance of about 3 mm.

Fig 6 Four-mm-diameter abutment placed on 5-mm-diameter implant distances contaminated interface from bone; thus, degree of bone resorption is limited. Even if two implants are positioned close to each other, thanks to platform-switching concept, interproximal bone height is not reduced after 1 year.



One solution requires the use of an implant design in which the shoulder follows the natural bone level circumferentially at a distance of about 1.5 mm above the bone level, ie, the scalloped implant.¹⁶ This implant is designed mainly to avoid bone loss in the interimplant area (papillary area). Long-term results will have to prove that the bone between two scalloped implants placed at a distance of 3 mm or less will not be resorbed over time. The disadvantage of such a design is the possible exposure of the implant collar if bone resorption occurs anyway.

Another solution involves the concept of platform switching, which seems to be more promising. This is based on the observation that, when the interface between the implant shoulder and abutment is moved horizontally away from the bone, bone resorption does not occur (Fig 6). This might be the result of distancing the contaminated microgap away from the bone. So far, only clinical experience of several years, but no scientific study, supports this hypothesis. The disadvantage of this concept is the fact that if normally sized abutments are to be used, wide-diameter implants have to be placed; this is not possible in many clinical situations. If, instead, regularly sized implants are used, small abutments would be necessary; in case of the replacement of a central incisor, for example, this may compromise the emergence profile. The platform-switching concept allows one to maintain the bone height around the implants and still use the

entire space down to the bone level prosthetically, which is not possible with scalloped implants.

Conclusion

To achieve a long-lasting, ideal esthetic result with implants in light of the circumferential bone resorption around the implant heads that has to be expected, the thickness of the bone on the buccal side of an implant should be at least 2 mm. As this is often not the case, most clinical cases will therefore need a bone augmentation procedure. For a papilla between two adjacent implants to be established, the interimplant distance has to be more than 3 mm. Alternatively, an additional bone volume on the buccal side of the papilla is required. The platform-switching concept seems to be a promising strategy to reduce or eliminate bone loss around the implant, especially in those cases where the ideal anatomic relationships do not exist, but scientific data have yet to be elaborated.

Acknowledgment

The authors wish to thank Mr Hans-Peter Spielmann, CDT, for the fabrication of the prostheses shown in this article.

References

1. Berglundh T, Lindhe J, Ericsson I, Marinello C, Liljenberg B, Thomsen P. The soft tissue barrier at implants and teeth. *Clin Oral Implants Res* 1991;2:81–90.
2. Abrahamsson I, Berglundh T, Wennström J, Lindhe J. The peri-implant hard and soft tissues at different implant systems. *Clin Oral Implants Res* 1996;7:212–219.
3. Cochran DL, Hermann JS, Schenk RK, Higginbottom FL, Buser D. Biologic width around titanium implants. A histometric analysis of the implant-to-gingival junction around unloaded and loaded nonsubmerged implants in the canine mandible. *J Periodontol* 1997;68:186–198.
4. Abrahamsson I, Berglundh T, Glantz PO, Lindhe J. The mucosal attachment at different abutments. An experimental study in dogs. *J Clin Periodontol* 1998;25:721–727.
5. Hermann JS, Buser D, Schenk RK, Higginbottom FL, Cochran DL. Biologic width around titanium implants. A physiologically formed and stable dimension over time. *Clin Oral Implants Res* 2000;11:1–11.
6. Van der Velden U. Regeneration of the interdental soft tissue following denudation procedure. *J Clin Periodontol* 1982;9:455–495.
7. Kois JC. The restorative-periodontal interface: Biological parameters. *Periodontol* 2000 1996;11:29–38.
8. Grunder U. Stability of the mucosal topography around single tooth implants and adjacent teeth: 1-year results. *Int J Periodontics Restorative Dent* 2000;20:11–17.
9. Kan JYK, Rungcharassaeng K, Umezu K, Kois J. Dimensions of peri-implant mucosa: An evaluation of maxillary anterior single implants in humans. *J Periodontol* 2003;74:557–562.
10. Salama H, Salama MA, Garber D, Adar P. The interproximal height of bone: A guidepost to predictable aesthetic strategies and soft tissue contours in anterior tooth replacement. *Pract Periodontics Aesthet Dent* 1998;10:1131–1141.
11. Grunder U, Spielman HP, Gaberthüel T. Implant-supported single tooth replacement in the aesthetic region: A complex challenge. *Pract Periodontics Aesthet Dent* 1996;8:835–842.
12. Adell R, Lekholm U, Rockler B, Brånemark P-I. A 15-year study of osseointegrated implants in the treatment of the edentulous jaw. *Int J Oral Surg* 1981;10:387–416.
13. Tarnow DP, Cho SC, Wallace SS. The effect of inter-implant distance on the height of inter-implant bone crest. *J Periodontol* 2000;71:546–549.
14. Esposito M, Ekkestubbe A, Grondahl K. Radiological evaluation of marginal bone loss at tooth surfaces facing single Brånemark implants. *Clin Oral Implants Res* 1993;4:151–157.
15. Spray RJ, Black CG, Morris HF, Ochi S. The influence of bone thickness on facial marginal bone response: Stage 1 placement through stage 2 uncovering. *Ann Periodontol* 2000;5:119–128.
16. Wöhrle PS. Nobel Perfect esthetic scalloped implant: Rationale for a new design. *Clin Implant Dent Relat Res* 2003;5(suppl 1):64–73.