

Identification of Stability Changes for Immediately Placed Dental Implants

Jason D. West, DDS, MS¹/Thomas W. Oates, DMD, PhD²

Purpose: To evaluate the changes in stability of immediately placed implants over a 6-month healing period relative to implants placed in native bone and to compare the stability of 2 different implant designs when placed as immediate implants in extraction sites. **Materials and Methods:** This prospective cohort study evaluated 3 implant patient populations. The control group (9 patients, 11 implants) required a single-stage, 1-piece, rough-surface implant (considered a “standard” implant) placed in nongrafted sites at least 6 months postextraction. The 2 experimental groups (25 patients, 28 implants) required extraction and immediate placement of either standard implants (12 patients) or tapered, self-tapping implants (13 patients). Immediate implant placement was carried out at the time of tooth extraction. Resonance frequency analysis (RFA), a measure of implant stability, was performed following implant placement at 2- to 4-week intervals for the first 16 weeks and at 24 weeks for immediate implants. **Results:** Placement protocol (control versus immediate placement) resulted in significant ($P < .001$) differences in implant stability, even though there was no difference ($P > .90$) in initial, mechanical implant stability between these groups. The immediately placed implants had significantly greater reductions in stability, approximately 15%, from baseline to 4 weeks. Immediate implant stability was consistent with that of implants placed in native bone after 12 to 16 weeks. Implant design did not have a significant effect on stability. **Conclusions:** This study demonstrates that immediate placement protocols are viable options and that standard-design implants may provide levels of biologic stability similar to a tapered, self-tapping implant design in immediate placement protocols. Most importantly, this study documents high levels of metabolic activity in the supporting osseous tissue following immediate placement, which may extend time to restoration compared with traditional implant placement. (Clinical Trial) *INT J ORAL MAXILLOFAC IMPLANTS* 2007;22:623–630

Key words: dental implants, implant stability, resonance frequency analysis, tooth extraction

Immediate placement of an endosseous dental implant into a tooth extraction site provides an intriguing option in implant therapy. This therapeutic approach offers the potential to significantly shorten overall treatment time as well as decrease the number of surgical experiences required by the patient. While clinical documentation supports the utilization of immediate implant placement, there remain important limitations in the scientific knowledge underlying its application.

Immediate implant placement represents an extension of the principles of guided bone regeneration. It involves osseous grafting and the use of barrier membranes to minimize the residual defect and promote osseointegration along the exposed implant surface.^{1–7} Optimizing bone formation with these techniques was thought to require soft tissue coverage of the implant site.^{2,5,8–15} However, alternative protocols for immediate implants have also reported high rates of success. For example, the transgingival placement of implants in extraction sites has demonstrated success, with the potential to eliminate the need for stage-2 surgery.^{16–20} Furthermore, the use of barrier membranes and grafting materials as applied in guided bone regeneration may not be required in many immediate implant situations.^{6,13,21}

The successes reported with immediate placement allow us to further consider current techniques, such as the healing time necessary prior to restoration. Although once up to 6 months of healing

¹Private Practice, The Woodlands, Texas; formerly Resident, Department of Periodontics, University of Texas Health Science Center at San Antonio, Texas.

²Associate Professor, Department of Periodontics, University of Texas Health Science Center at San Antonio, Texas.

Correspondence to: Dr Thomas Oates, Department of Periodontics, UTHSCSA, 7703 Floyd Curl Drive, San Antonio, TX 78229-3900. E-mail: oates@uthscsa.edu

prior to a restoration was thought necessary, implants have been successfully loaded within 24 hours of the surgical visit.²² There are, however, little data to support the development of alternative strategies for restoration. Importantly, successful restoration of immediate implants may be dependent on the underlying physiologic changes occurring at the bone-implant interface. Understanding these biologic processes may prove critical in defining appropriate strategies for restoration (ie, determining when loading can be accomplished without adversely affecting osseointegration of the implant).

Recently developed technologies allow us to examine the osseointegration process by assessing implant stability. One such technology, resonance frequency analysis (RFA), has been shown to correlate with clinical assessments of bone density and osseous changes reflective of metabolic activity following implant placement.²³⁻²⁶ Over time, changes in the stability of the system were found to be reflective of biologic changes at the bone-implant interface consistent with osseointegration.²³

The use of RFA in conjunction with a nonsubmerged approach to immediate implant placement allows an assessment of the metabolic activity associated with the bone-implant interface during the healing period following implant placement. Therefore, the purpose of this prospective study was to evaluate the changes in stability for transgingival implants placed immediately into extraction sites during the 6-month healing period following implant placement using RFA. In addition, the stability of a tapered, self-tapping design transgingival implant was compared to a standard implant lacking tapered, self-tapping characteristics.

MATERIALS AND METHODS

This cohort study was designed to prospectively evaluate healing along the bone-implant interface of immediately placed implants compared to implants placed in native bone. Implant stability was assessed using RFA over the duration of the healing period (Osstell; Integration Diagnostics, Svedalen, Sweden). RFA was performed at the time of implant placement and at 2- to 4-week intervals up to 16 weeks for all implants, as well as at 24 weeks postplacement for immediate implants. All implants were placed with transgingival healing caps to allow direct access for RFA, but the implants did not receive any prosthetic restoration until after study completion.

Patient Population

The study population consisted of dental patients at the University of Texas Health Science Center at San

Antonio (UTHSCSA). For the control group, patients with edentulous regions who had undergone a healing period of at least 6 months following extraction were considered for standard implant placement in native bone (9 patients, 11 implants). For the experimental groups, patients in need of an extraction of a premolar or anterior tooth in either the maxillary or the mandibular arches were considered. Following tooth extraction, all sites providing clinical implant stability (no clinically visible movement) were enrolled in the study (25 patients, 28 implants). Informed consent was obtained for all subjects in accord with policies and procedures of the UTHSCSA Institutional Review Board. Subjects were excluded from the study if they reported smoking more than 10 cigarettes per day or current chemotherapy or had a history of drug or alcohol abuse, untreated periodontitis, poorly controlled systemic disease, or radiation to the head or neck.

Experimental Group

Standard-diameter (4.1 mm) Straumann sand-blasted, large-grit, acid-etched (SLA) Standard Plus (standard) or Tapered Effect (tapered, self-tapping) implants (Straumann, Waldenburg, Switzerland) were used for immediate placement. Implant length ranged from 8 to 14 mm, with a majority (25 of 28) being 10 or 12 mm. Determination of the implant design placed into the extraction site was sequential in nature. The first 15 immediate implants placed in 12 patients were standard implants, with the next 13 implants being the tapered implants placed in 13 patients, for a total of 28 implants. For the surgical procedure, sulcular incisions were made around the tooth to be extracted. The facial gingival tissues were minimally reflected in full-thickness flaps, exposing the osseous crest circumferentially around the socket. Flap reflection was kept to a minimum (not extending beyond the mucogingival junction) unless a complication arose that required more extensive flap elevation. Complications included apical fenestration or dehiscence of the alveolar housing. No implants were removed from the study because of lack of primary stability. The extractions were kept as minimally traumatic as possible to the surrounding tissues; damage to the interdental bone and facial plate was avoided. After extraction, any visible soft tissue fragments were removed from the extraction site by a curette or Hirshfield file (Hu-Friedy, Chicago, IL). For implant placement, emphasis was placed on apical engagement of the implant to the osseous housing only when mesial and distal engagement along the walls of the socket was not feasible.

After placement of the implant, RFA was performed by attaching the L-shaped transducer to the implant using the internal threads of the implant.

This procedure was repeated 3 times on each implant. The transducer was loosened and tightened between readings. The transducers were calibrated for accuracy using an implant fixed in an aluminum block (Osstell; Integration Diagnostics, Savedalen, Sweden). The RFA device has a central processing unit that converts the resonance frequency measured in hertz to quantitative units termed the implant stability quotient (ISQ). ISQ measures clinical stiffness; it ranges 1 to 100. As ISQ values increase, implant stability also increases.^{24–26} Following RFA, an extended healing cap was placed on the implant to keep the implant transgingival. A periodontal probe was used to measure the distance from the implant surface to the internal aspect of the buccal or lingual plate (horizontal defect dimension [HDD]). If the HDD was less than 2 mm, no grafting was performed. If the defect was greater than or equal to 2 mm, freeze-dried bone allograft (FDBA; LifeNet, Virginia Beach, VA) was placed in the defect, which was filled to the crest. No barrier membranes were placed to cover the defect in any case. Mucosal flaps were then approximated using chromic-gut sutures in an interrupted fashion.

RFA was carried out at 2, 4, 6, 8, 10, 12, 14, 16, and 24 weeks after the surgical visit. Each visit entailed removal of the healing abutment and placement of the transducer in the same manner as described for the surgical appointment. RFA measurements were again recorded in triplicate. The examiner was blinded as to RFA readings at previous visits but was not blinded as to the placement approach (ie, control versus test group).

Control Group

The control group consisted of 9 patients (11 implants) having a partially edentulous region requiring at least 1 dental implant. The implant sites required at least 6 months of healing following tooth extraction. Sites requiring guided bone regeneration in addition to implant placement were excluded from the study. For implant placement, midcrestal incisions with full-thickness buccal and lingual flaps were reflected. Osteotomies were prepared according to the manufacturer's guidelines for the placement of a 4.1-mm-diameter standard implant either 10 or 12 mm in length. All implants were placed in either type 2 or type 3 bone consistent with classifications of Lekholm and Zarb.²⁷ RFA measurements were performed following the protocol described for the experimental group at surgical and postoperative appointments. A transgingival healing cap was placed on each implant. RFA measurements were recorded at baseline (week 0), and 2, 4, 6, 8, 12, and 16 weeks after the surgical visit.

Statistical Analysis

Three sets of 2-factor mixed-model analysis of variance (ANOVA) were performed to check whether changes across time varied depending on (1) the type of implant (native bone, immediate—standard or immediate—TE), (2) whether the implant was placed immediately or in a delayed manner (ie, standard and TE combined versus native bone), and (3) whether initial stability of the immediate implants was considered high or low (ie, native bone, immediate implants with initial ISQ < 56 and immediate implants with initial ISQ > 56). The second set of analyses that were performed excluded native bone implants and included all follow-up times for the immediately loaded implants.

Three sets of 2-factor mixed-model ANOVAs were performed to check whether changes across time varied for immediately placed implants depending on (1) the type of implant (standard versus TE), (2) implant location (anterior maxilla, posterior maxilla, or mandible), and (3) initial stability (low versus high). The covariance structure for the repeated factor of week in each of the mixed model ANOVAs was assumed to be first-order autoregressive and heterogeneous. A consistent approach to the interpretation was employed in the analysis of the mixed-model ANOVAs. If the interaction term for the 2-factor model was statistically significant ($P < .10$), then Bonferroni-adjusted Student *t* tests were performed to check for mean differences within each follow-up time, with $P < .05$ considered significant. If the interaction term was not significant, then the main effects for the 2 factors were checked, with $P < .05$ considered significant. If the main effect for follow-up time was significant, then Bonferroni-adjusted Student *t* tests, with $P < .05$ considered significant, were performed to check for mean differences among follow-up times within groups defined by the other factor in the model. Bonferroni adjustment was applied to the related Student *t* test *P* values so that the critical value was maintained at .05.

For the population of patients requiring implants, a difference between treatment groups in mean ISQ of 5 or more at a given healing time would be considered clinically significant. A power analysis performed using PASS 6.0 software (NCSS, Kaysville, VT) determined that the sample size was sufficient to detect a population mean ISQ difference of 5 or more with a population standard deviation of 3.5 or less with a Bonferroni-adjusted Student *t* test at the .05 level with a power of 81%.

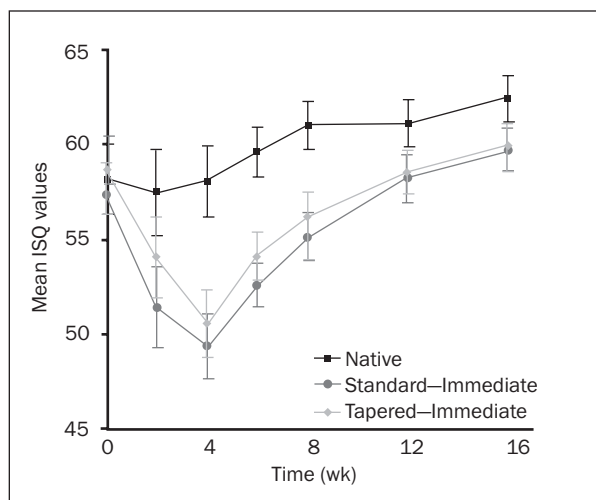


Fig 1 Stability changes with respect to placement protocol and implant type. Mean ISQ values (\pm SD) for standard dental implants placed in native bone or standard or tapered implants placed in extraction sockets.

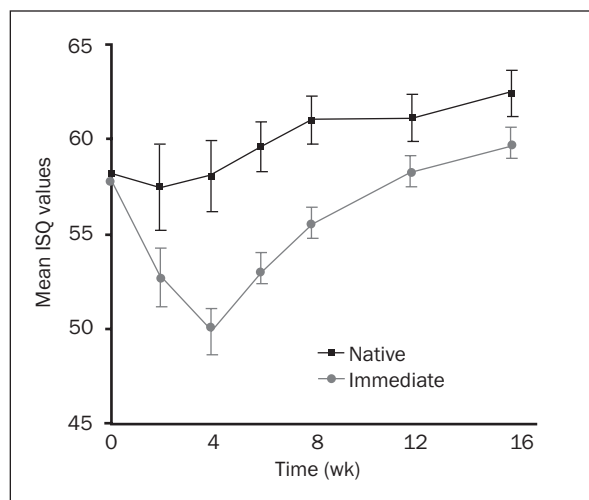


Fig 2 Stability changes based on placement protocol. Mean ISQ values (\pm SD) for standard dental implants placed in native bone or immediate implant placement (data for standard and tapered implants combined).

RESULTS

All 25 patients (28 implants) enrolled in the experimental group for this study received immediate implant placement. The experimental group consisted of 14 female patients and 11 male patients ranging in age from 27 to 78 years (mean, 54.6 years). Of the 28 SLA Straumann implants placed transgingivally into extraction sites (experimental group), 1 implant (3.57%) failed during the second week of healing. This implant, a standard implant, was subsequently removed. Therefore, statistical analysis was carried out on the 27 successfully osseointegrated immediate implants. All 11 implants placed in native bone (control group) were successfully osseointegrated. The control group consisted of 7 female patients and 2 male patients with an age range of 29 to 59 years (mean, 44.2 years).

The 27 immediate implants evaluated were placed in maxillary and mandibular anterior and premolar locations. Implants in the control group (native bone) were placed in maxillary and mandibular posterior sites in type 2 or 3 bone. Maxillary anterior sites received 37% (10) of the immediately placed implants, with 70% (7 of 10) of these implants placed in the central incisor location. Overall, immediate implants were placed in the maxilla, and 7 were placed in the mandible. Only 1 of the 7 implants placed in the mandible was located in the mandibular anterior; the remainder of the implants were placed in premolar sites. Regarding the removed teeth, 25.9% (7) were extracted for endodontic reasons, 48.1% (13) were removed for prosthetic reasons, and 25.9% (7) were extracted because of fractures, resorption, or iatrogenic perforations.

Taken collectively across all weeks and implants, the average RFA data generally followed an approximately normal distribution, with an overall skewness of -0.64 and kurtosis of 0.45 . Initial analysis of the 3 implant types/protocols over time showed a significant difference in stability ($F = 2.28$, $P < .015$), with significantly greater stability for implants in native bone compared to both standard and tapered immediate implants at 4, 6, and 8 weeks ($P < .035$, Fig 1). There was no significant difference in initial stability (week 0) between any of the implant types. The mean levels of stability also did not differ significantly among implant types at weeks 2, 12, or 16 ($P > .15$). The 2 implant designs, tapered and standard, used in the immediate placement protocol were compared to each other relative to implant stability. Even though the tapered design with a self-tapping thread pattern is thought to provide better stability in immediate placement compared to standard design, there was no significant difference between tapered and standard implants over the entire 16 weeks ($P > .40$). Therefore, results of both implant designs were combined in further analyses.

Combining data from all 27 immediate implants for comparison with implants placed in native bone also identified significant differences in stability over time ($F = 4.40$, $P < .001$). The implants placed in native bone had significantly greater stability than immediately placed implants at 4, 6, and 8 weeks ($P < .005$), while marginal differences were observed at weeks 2 ($P = .093$), 12 ($P = .072$), and 16 ($P = .080$; Fig 2). Comparing immediate implants to implants in native bone at the time of placement (week 0) showed no difference in stability ($P > .90$).

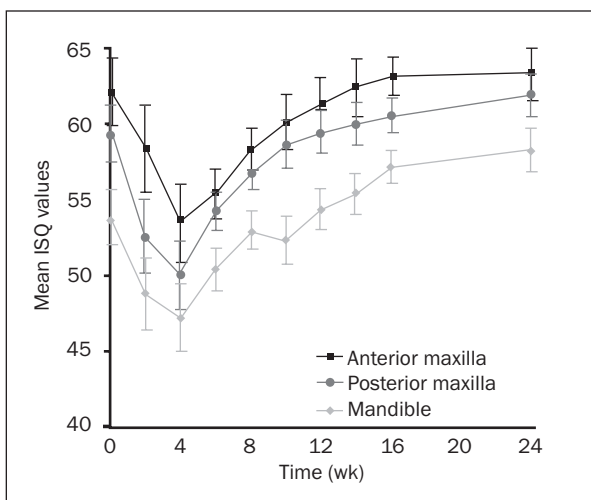


Fig 3 Effects of anatomic location of placement (mandible, anterior maxilla, or posterior maxilla). Mean ISQ values (\pm SD) for immediate implant placement (data for standard and tapered implants combined).

Figure 3 illustrates immediate implants grouped according to their anatomic location in the oral cavity. There were significant differences based on both anatomic location ($P < .001$) and time ($P < .001$). In general, implants placed in the mandible tended to have greater stability than implants placed in the anterior maxilla, with significant mean differences observed at baseline and weeks 2, 8, 10, 12, 14, and 16 ($P < .045$). Experimental implants placed in the mandible did not differ significantly from experimental implants placed in the posterior maxilla ($P > .30$). When implants placed into the anterior maxilla were compared to implants placed into the posterior maxilla, a significant statistical difference was demonstrated only at week 10 ($P < .03$). In all anatomic regions, the stability of the implants after 16 weeks matched or exceeded the stability levels found at baseline, with little change in stability for 16 through 24 weeks in all regions. The relative levels of stability found at implant placement (week 0) between each of these regions were maintained throughout the 24 weeks of evaluation. That is, the mandibular region showed the highest levels of stability at all time points, and the anterior maxilla showed the lowest levels of stability at all time points.

For implants placed in the anterior maxilla, stability decreased significantly from baseline to 2 and 4 weeks ($P < .04$), then increased significantly from 4 to 12 weeks ($P < .045$). For implants placed in the posterior maxilla, stability decreased significantly from baseline to 2 and 4 weeks ($P < .005$), then increased significantly from 4 to 8 weeks ($P < .020$). For implants placed in the mandible, stability decreased significantly from baseline to 4 weeks ($P < .005$), then

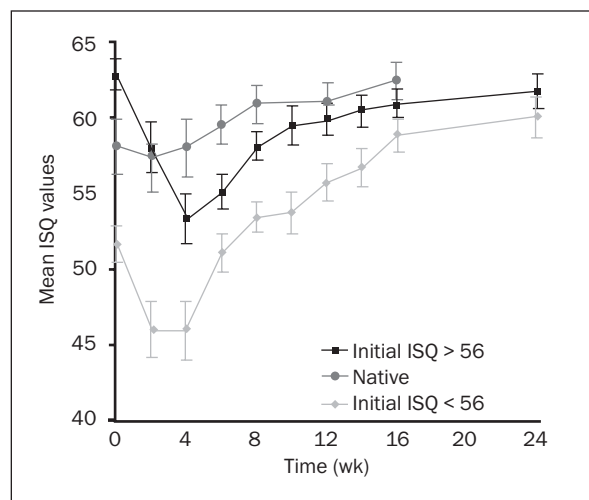


Fig 4 Stability changes over time based on level of stability at the time of placement. Mean ISQ values (\pm SD) are presented for standard implants in native bone and immediate implants having high (> 56 ISQ) or low (< 56 ISQ) initial stability.

increased significantly from 6 to 12 weeks ($P < .050$). Interestingly, looking at the decreases in stability on a percentage basis, there was a 12.25% decrease in stability in the anterior maxillary region, a 13.86% decrease in the mandible, and a 15.71% decrease in the posterior maxilla from baseline through 4 weeks. It is noteworthy that the smallest percent decrease in stability over the first 4 weeks occurred in the group with the lowest initial stability (anterior maxilla).

The healing patterns of immediately placed implants with larger defects (ie, those that received FDBA because HDD was at least 2 mm), were compared to those immediate implants with narrower defects that were not grafted (HDD < 2 mm). Both groups showed the same patterns of changes in stability found for the immediate implants overall. In fact, there was no significant difference in stability levels between grafted and nongrafted groups at any time point (data not shown).

As it is possible that the stability levels over time may be influenced by the initial stability of the implants, the data were grouped according to whether initial implant stability was high or low. To establish the threshold separating high and low implants, it was observed that the widest interval between initial ISQ values was an interval of 2.33 between the 11th and 12th lowest values (55.67 and 58.00). Implants with initial ISQ less than 56 were considered to have low initial stability, while implants with initial ISQ greater than 56 were considered to have high initial stability. Implant stability was significantly greater for the high-initial-stability group from week 0 through week 14 ($P < .03$; 0, 2, 8, 10 weeks, $P < .005$; Fig 4). However, there was no significant differ-

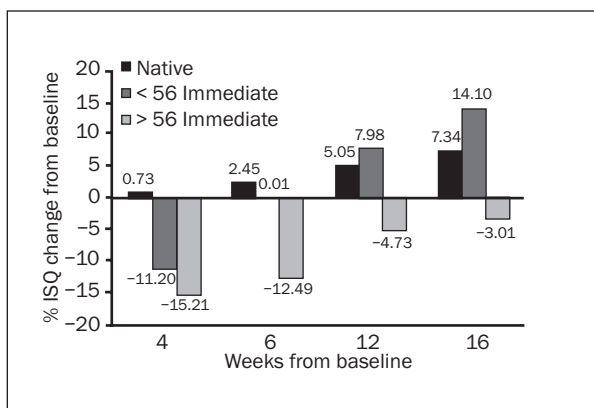


Fig 5 Percent changes in stability from baseline for implants placed in native bone or immediate implants having low (< 56 ISQ) or high (> 56 ISQ) initial stability.

ence in stability between the high and low groups by weeks 16 and 24 ($P > .10$). Immediate implants with high initial stability approached levels consistent with implants placed in native bone by week 12; however, immediate implants with low initial stability did not approach these levels until week 16.

Both groups of immediate implants showed decreases in stability of greater than 11% over the first 4 weeks. The percentage of decrease for high-initial-stability implants was greater than that of the low group (Fig 5). Interestingly, in looking at the changes in stability occurring between 4 and 6 weeks, the immediate implants with low initial stability showed an increase in stability of approximately 11%, compared with increases in stability of less than 3% for the other 2 groups. Between 6 and 12 weeks, both immediate implant groups (low and high initial stability) showed approximately an 8% increase in stability, compared with about 3% for implants in native bone. Between 12 and 16 weeks only the immediate implants with low initial stability showed continued increases in stability of greater than 4% with approximately a 6% increase in stability. The implants with less stability (< 56) also had the greater HDD and were countersunk approximately 0.5 mm more apically on average than implants with greater initial stability.

DISCUSSION

This study provides evidence in support of the clinical use of immediate implant placement protocols. The use of a nonsubmerged approach, the use of graft material without a barrier membrane, and the decision not to use bone grafting in smaller defects (HDD) are all supported by the results of the present study. Immediate placement of dental implants (ie, placement of an

implant at the same appointment as tooth extraction) using a transgingival protocol in this study had similar success rates to those achieved with implants placed in native bone (96.43% vs 100%). This success rate is consistent with those previously reported.^{2,5,28-30}

Initial stability (ISQ values at baseline) of immediate implants was not significantly different from implants placed in native sites; all implants were placed in sites with adequate osseous support. This lack of distinction in mechanical stability between native sites and immediate sites may be misleading clinically considering the dramatic decrease in stability in the immediate placement group over the first 4 weeks following implant placement. This biologic decrease in stability was approximately 67 times as great as the decrease seen in native bone and represented a drop approaching 15% of the overall initial stability. This dramatic decrease in stability during the first month following placement may prove detrimental to the long-term success of the implant, especially in circumstances where immediate or early restoration of the implants may be considered.

Implants placed in type 4 bone have been viewed differently from implants placed in higher-quality bone.^{27,31,32} These clinical impressions were validated using RFA data collected by Barewal et al,²³ who demonstrated an 8.6% decrease in stability in type 4 bone compared with a decrease of only 1% in type 1 bone. Comparing this to the present study, the decreases in stability associated with type 4 bone were approximately one-half of that found for immediate implants. If the implant integration for type 4 bone requires unique clinical considerations, these considerations are even more relevant in immediate implant placement. This special attention may be most appropriate in regard to early or immediate loading protocols and warrants additional investigation.

The changes in implant stability when evaluated over time are suggestive of the resorptive and formative activity for the supporting osseous tissues. The changes in stability associated with immediate implant placement suggest that this biologic stabilization of the implants may affect restorative protocols, warranting further investigation of the effects of restoration and functional loading on immediate implant stability.

The present results support the concept that initial mechanical stability of an immediate implant can be a valuable predictor of healing trends. Based on initial stability, it was possible to delineate 2 groups of immediate implants, high and low initial stability. Although implants can be loaded following as little as 6 weeks in native bone, the present findings suggest that a longer integration period is required for immediate implant loading, and that the time required may be dependent upon the level of initial

stability.^{32,33} Specifically, the present findings suggest that immediate implants that are initially very stable may be loaded in 8 to 12 weeks, whereas less stable immediate implants may require up to 16 weeks prior to loading, assuming that baseline levels of stability are appropriate for loading.

Both standard and tapered implant designs were placed immediately into extraction sites for this study. No significant difference was detected in the stability patterns with respect to implant design, although the tapered implant showed slightly higher stability levels compared with the standard implant. In fact, the stability patterns documented by the longitudinal assessment of mean ISQ values were nearly identical for the 2 implant designs. Based on the present findings, from a stability standpoint, the use of the self-tapping, tapered implant in extraction sites does not appear advantageous. These findings appear consistent with an evaluation of initial or mechanical stability using several self-tapping implant designs that found that a self-tapping component may not promote stability.³⁴ The results of the present study suggest that decreases in biologic stability following placement due to biologic remodeling during the integration process may be more significant than the gains in initial stability obtained with variations in current designs.

Immediate implants were also evaluated based on anatomic location in the oral cavity. Despite variations in location, immediately placed implants demonstrated the same overall stability patterns. However, lower stability measurements for the maxillary anterior region may have been due to anatomic differences between the bone in this region and that in mandibular sites. For example, there was often a large moat-like defect after implant placement in the anterior maxilla due to the root anatomy of central incisors, whereas root anatomy of premolar sites was often narrow or ribbon shaped, potentially allowing for more engagement of the lateral walls at implant insertion. Also, bone quality is often of less density in the maxilla compared to the mandible.²⁷ Since only premolar sites were considered for immediate implant placement in the posterior maxilla, the difference in stability measurements between the 2 regions in the maxilla may be attributed to defect morphology, since bone quality was similar.

One of the limitations of the study is that comparisons could not be made between similar or matched sites or tooth positions. Also, it was not possible to determine the relationship of the residual bone anatomy relative to the engagement of the implant within bone between sites. It is possible that different approaches to immediate implant placement may respond differently than that used in this study.

Grafting of larger defects (HDD \geq 2 mm) with FDBA seemed to provide a similar level of stability to that achieved with immediate implants with smaller defects (< 2 mm), which were not grafted. Non-grafted defects < 2 mm around implants have been documented by Wilson et al⁶ and Paolantonio et al¹³ and shown to have bone-implant contact similar to implants placed in native bone after healing. One reason for this may be that as the implants were being placed, when larger horizontal defects were observed, the surgeon tended to countersink the implant more apically than if a smaller defect was observed. This is supported by the present results. Grafted sites had a mean horizontal defect of 2.79 mm and a countersinking of 1.46 mm, whereas non-grafted sites had a mean horizontal defect of 1.53 mm and a countersinking of 1.0 mm. In other words, grafted sites had mean defects 1.26 mm larger than nongrafted sites and were placed 0.46 mm more apically in the bone, resulting in only a 1.6% difference in initial stability measurements between the 2 groups. Also, Botticelli et al³⁵ showed that large (2.25 mm) and small (1.25 mm) self-contained defects around implants showed similar amounts of defect resolution and were significantly more resolved than defects without a buccal wall. This suggests that it may be not the size of the defect, but the formation and stabilization of the coagulum within the defect that affects defect resolution and subsequent implant stabilization. Consistent with the present findings, Botticelli et al³⁶ demonstrated that self-contained defects \geq 3 mm could completely resolve after 4 months of healing in humans without the use of grafting materials or barrier membranes.

In summary, this prospective clinical study documented the alterations in stability for immediate implants during the metabolically active healing period following placement. It reinforces earlier histologic investigations of bone healing adjacent to implants and extends existing knowledge to identify changes in implant stability specifically associated with biologic alterations of the bone-implant interface. By closely evaluating implant stability during the healing period, this study provides valuable insights into the impact of the biologic processes on the integration process. Most importantly, this study shows that immediate placement therapy requires consideration of factors during the early integration period that may affect time to restoration compared with traditional implant placement.

ACKNOWLEDGMENTS

The authors would like to thank Mr John Schoolfield for his statistical analysis of the data and Ms Madge Cluck for her assistance with this publication. This study was supported by the ITI Foundation.

REFERENCES

- Cornelini R, Scarano A, Covani U, Petrone G, Piattelli A. Immediate one-stage postextraction implant: A human clinical and histologic case report. *Int J Oral Maxillofac Implants* 2000;15:432–437.
- Gelb DA. Immediate implant surgery: Three-year retrospective evaluation of 50 consecutive cases. *Int J Periodontics Restorative Dent* 1993;8:388–399.
- Lazzara R. Immediate implant placement into extraction sites: Surgical and restorative advantages. *Int J Periodontics Restorative Dent* 1989;9:332–343.
- Novaes AB, Novaes AB. IMZ implants placed into extraction sockets in association with membrane therapy (Gengiflex) and porous hydroxyapatite. A case report. *Int J Oral Maxillofac Implants* 1992;7:536–540.
- Schwartz-Arad D, Grossman Y, Chaushu G. The clinical effectiveness of implants placed immediately into fresh extraction sites of molar teeth. *J Periodontol* 2000;71:839–844.
- Wilson T, Schenk R, Buser D, Cochran D. Implants placed in immediate extraction sites: A report of histologic and histometric analyses of human biopsies. *Int J Oral Maxillofac Implants* 1998;13:333–341.
- Wilson T, Carnio J, Schenk R, Cochran D. Immediate implants covered with connective tissue membranes: Human biopsies. *J Periodontol* 2003;74:402–409.
- Becker W, Becker BE, Polizzi G, Bergström C. Autogenous bone grafting of bone defects adjacent to implants placed into immediate extraction sockets in patients: A prospective study. *Int J Oral Maxillofac Implants* 1994;9:389–396.
- Evian C, Cutler S. Autogenous gingival grafts as epithelial barriers for immediate implants: Case reports. *J Periodontol* 1994;3:201–210.
- Goldstein M, Boyan BD, Schwartz Z. The palatal advanced flap: A pedicle flap for primary coverage of immediate placed implants. *Clin Oral Implants Res* 2002;13:644–650.
- Nemcovsky C, Artzi Z, Mes O. Rotated split palatal flap for soft tissue primary coverage over extraction sites with immediate implant placement. Description of the surgical procedure and clinical results. *J Periodontol* 1999;70:926–934.
- Nemcovsky C, Artzi Z, Mes O. Rotated palatal flap in immediate implant procedures. *Clin Oral Implants Res* 2000;11:83–90.
- Paolantonio M, Dolci M, Scarano A, et al. Immediate implantation in fresh extraction sockets. A controlled clinical and histological study in man. *J Periodontol* 2001;72:1560–1571.
- Yukna RA. Clinical comparison of hydroxyapatite-coated titanium dental implants placed in fresh extraction sockets and healed sites. *J Periodontol* 1991;62:468–472.
- Yukna RA, Saenz AM, Shannon M, Mayer ET, Castellon P. Use of HTR synthetic bone as an augmentation material in conjunction with immediate implant placement: A case report. *J Oral Implantol* 2003;29:24–28.
- Bragger U, Hammerle CH, Lehman B, Lang NP. Immediate transmucosal implants placed into extraction sockets. *J Dent Res* 1993;72:311.
- Bragger U, Hammerle CH, Lang NP. Immediate transmucosal implants using the principle of guided tissue regeneration (II). A cross-sectional study comparing the clinical outcomes 1 year after immediate standard placement. *Clin Oral Implants Res* 1996;7:268–276.
- Hammerle CH, Bragger U, Schmid B, Lang NP. Successful bone formation at immediate transmucosal implants: A clinical report. *Int J Oral Maxillofac Implants* 1998;13:522–530.
- Lang NP, Bragger U, Hammerle CH, Sutter F. Immediate transmucosal implants using the principle of guided tissue regeneration. I. Rationale, clinical procedure and 30-month results. *Clin Oral Implants Res* 1994;5:154–163.
- Schultz AJ. Guided tissue regeneration (GTR) of nonsubmerged implants in immediate extraction sites. *Pract Periodontics Aesthet Dent* 1993;5:59–65.
- Covani U, Cornelini R, Barone A. Bucco-lingual bone remodeling around implants placed into immediate extraction sockets: A case series. *J Periodontol* 2003;2:268–273.
- Aires I, Berger J. Immediate placement in extraction sites followed by immediate loading: A pilot study and case presentation. *Implant Dent* 2002;11:87–94.
- Barewal R, Oates TW, Meredith N, Cochran DL. Resonance frequency measurement of implant stability in vivo on implants with a sandblasted and acid-etched surface. *Int J Oral Maxillofac Implants* 2003;5:641–651.
- Meredith N, Alleyne D, Cawley P. Quantitative measurement of the stability of the implant-tissue interface using resonance frequency analysis. *Clin Oral Implants Res* 1996;7:261–267.
- Meredith N, Book K, Friberg B, Jemt T, Sennerby L. Resonance frequency measurements of implant stability in vivo. A cross-sectional and longitudinal study of resonance frequency measurements on implants in the edentulous and partially dentate maxilla. *Clin Oral Implants Res* 1997;8:226–233.
- Meredith N, Shagaldi F, Alleyne D, Sennerby L, Cawley P. The application of resonance frequency measurements to study the stability of titanium implants during healing in the rabbit tibia. *Clin Oral Implants Res* 1997;8:234–243.
- Lekholm U, Zarb GA. Patient selection and preparation. In: Brånemark P-I, Zarb GA, Albrektsson T (eds). *Tissue-Integrated Prosthesis: Osseointegration in Clinical Dentistry*. Chicago: Quintessence, 1985:199–210.
- Gher ME, Quintero G, Assad D, Monaco E, Richardson AE. Bone grafting and guided bone regeneration for immediate implants in humans. *J Periodontol* 1994;65:881–891.
- Schwartz-Arad D, Chaushu G. Placement of implants into fresh extraction sites: 4 to 7 retrospective evaluation of 95 immediate implants. *J Periodontol* 1997;68:1110–1116.
- Becker W, Sennerby L, Bedrossian E, Becker B, Lucchini JP. Implant stability measurements for implants placed at the time of extraction: A cohort, prospective clinical trial. *J Periodontol* 2005;76:391–397.
- Jaffin RA, Berman CL. The excessive loss of Brånemark fixtures in type IV bone. A 5-year analysis. *J Periodontol* 1991;62:2–4.
- Cochran DL, Buser D, ten Bruggenkate CM, et al. The use of reduced healing times on ITI implants with a sandblasted and acid-etched (SLA) surface: Early results from clinical trials on ITI SLA implants. *Clin Oral Implants Res* 2002;13:144–153.
- Bornstein MM, Lussi A, Schmid B, Belser UC, Buser D. Early loading of nonsubmerged titanium implants with a sandblasted and acid-etched (SLA) surface: 3-year results of a prospective study in partially edentulous patients. *Int J Oral Maxillofac Implants* 2003;18:659–666.
- O'Sullivan D, Sennerby L, Meredith N. Influence of implant taper on the primary and secondary stability of osseointegrated titanium implants. *Clin Oral Implants Res* 2004;15:474–480.
- Botticelli D, Berglundh T, Lindhe J. Resolution of bone defects of varying dimension and configuration in the marginal portion of the peri-implant bone. An experimental study in dog. *J Clin Periodontol* 2004;31:309–317.
- Botticelli D, Berglundh T, Lindhe J. Hard-tissue alterations following immediate implant placement in extraction sites. *J Clin Periodontol* 2004;31:820–828.