

Maxillary Sinus Lift for Single Implant-Supported Restorations: A Clinical Study

Gerald Krennmair, MD, DMD, PhD^{1,2}/Martin Krainhöfner, MD, DMD³/
Martina Schmid-Schwab, MD, DMD⁴/Eva Piehslinger, MD, DMD, PhD⁴

Purpose: The aim of this study was to evaluate single-tooth implant-supported restorations placed in conjunction with several methods of maxillary sinus augmentation. **Materials and Methods:** A retrospective review was conducted of all consecutively treated patients who received single-implant tooth rehabilitation in combination with sinus augmentation. Implant survival rate and peri-implant conditions, such as marginal bone resorption (mm), pocket depth (mm), Plaque and Bleeding Indices, and Periotest values, were compared for the different augmentation procedures. **Results:** Fifty-one patients were treated with 54 screw-type single implant-supported restorations in the posterior maxilla in combination with isolated sinus floor augmentation. Depending on the residual ridge height and the intended augmentation height, sinus lift elevation was performed either in a 1-stage lateral approach (25 patients, 28 implants), in a 2-stage lateral approach (12 patients, 12 implants), or with the osteotome technique (14 patients, 14 implants). The predominant use of long implants provided for a favorable implant-crown ratio (> 1.0) and produced an overall clinical survival rate of 100% over the observation period (44.5 ± 22.7 months), with no differences between the augmentation procedures and implant types used. The most frequent site for single-tooth replacement in combination with sinus floor augmentation was the first molar region (61%). Implants with wider diameters (94% ≥ 4.3 mm) were used in this region. The most frequent intraoperative complication was tearing of the sinus membrane (58%) as a result of the restricted access for the lateral 1- or 2-stage approach, and the most frequent prosthetic complication was crown loosening. **Conclusion:** On the basis of this retrospective review, the following was observed: (1) Successful function and excellent peri-implant parameters may be anticipated for single implant-supported restorations placed in conjunction with sinus elevation procedures. (2) Clinical and radiographic examinations demonstrated similar conditions for single-tooth restorations despite the use of different surgical approaches to sinus augmentation. (More than 50 references.) INT J ORAL MAXILLOFAC IMPLANTS 2007;22:351–358

Key words: lateral approach, osteotome technique, single implant-supported restorations, sinus augmentation

In the posterior maxilla, standard implant placement is often restricted because of generally reduced bone quality and quantity.^{1–3} During the last

3 decades, surgical procedures have been developed to increase the local bone volume, thus allowing the placement of implants in the posterior maxilla in patients with initially insufficient bone height.^{3–5} In situations where the lack of sufficient bone volume is related to an enlarged maxillary sinus, sinus floor elevation has been advocated to allow implant placement even when the posterior maxillary region has undergone severe bone resorption.^{2–5} Among the variety of sinus floor elevation techniques described in literature, the 1- or 2-step lateral approach and the crestal approach using the osteotome technique are the most widely used.^{3,4,6–12}

The surgical technique chosen may depend on the residual ridge bone height, the implant length, and the amount of bone grafting required.^{3,4,9–12} Various types of grafting materials have been success-

¹University Professor and Clinical Lecturer, Dental School, University of Vienna, Austria.

²Private Practice, Oral Implantology and Implant Prosthetics, Wels, Austria.

³Assistant, Department of Prosthodontics, Dental School, University of Vienna, Austria.

⁴Head, Department of Prosthodontics, Dental School, University of Vienna, Austria.

Correspondence to: Univ Doz DDr Med Gerald Krennmair, Trauneggsiedlung 8, 4600 Wels, Austria. Fax: ++ 7243 518136. E-mail: krennmair@aon.at

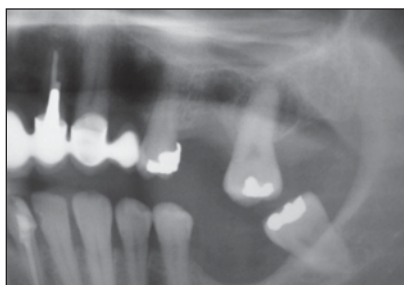


Fig 1 Preoperative panoramic radiograph demonstrating insufficient alveolar bone for a single implant-supported restoration in the first molar region.

fully utilized for sinus augmentation, especially when using the lateral approach. Autogenous bone, xenogenic bone, or a mixture of materials may be used for sinus augmentation; all of these have been associated with high success rates.^{3,4,6-8} The number of stages used (1 or 2) depends on the residual ridge height (ie, being greater or less than 5 mm) and on the possibility of achieving primary stability of implants placed.^{4-6,9-12} According to standard protocol, the osteotome technique can be used when the ridge height is more than 6 mm where implants are placed simultaneously with elevation of the sinus floor.⁹⁻¹¹ In contrast to the nearly unlimited possibilities of membrane elevation in the antrostomy technique, the osteotome procedure cannot be used to elevate the sinus membrane more than 5 or 6 mm.^{12,13} Regardless of the surgical procedure selected and the augmentation material used, sinus augmentation can be a successful treatment option for implant placement in primarily reduced maxillary posterior regions.³⁻¹²

Although modern surgical techniques and the patients' wishes of achieving optimal rehabilitation have led clinicians to consider sinus lift augmentation even for single implant-supported restorations, there is still a paucity of detailed reports on single implant-supported restorations used in conjunction with maxillary sinus augmentation. A number of articles describe high survival and success rates of single-tooth implants and restorations.¹⁴⁻¹⁹ However, most of the studies describe evaluations of single implant-supported restorations predominately placed in the maxillary esthetic anterior region or are sampled investigations of implant placement in overall jaw locations.^{15-17,19-21} There is a lack of detailed information on the combined results of single-tooth implants placed in conjunction with sinus elevation.²² The present study reports the results of single implant-supported restorations placed in maxillary bone augmented using either the osteotome or lateral augmentation technique.

MATERIALS AND METHODS

Patient Selection

A retrospective review was conducted of all patients who underwent single implant placement in the posterior maxilla with sinus augmentation using the osteotome or lateral augmentation technique from March 1996 through October 2003.

All patients had been treated at least 2 years, and all were included in a regular recall program. Patients were treated with maxillary single-tooth implant-supported restoration in conjunction with sinus floor augmentation if (1) their remaining teeth were intact, (2) the teeth adjacent to the edentulous areas were treated with minimal/optimal prosthodontic restorations (inlay/crowns), or (3) the teeth adjacent to the edentulous area showed signs of periodontal bone resorption precluding the fabrication of fixed partial dentures.

Implants

Screw-type implants were used for all patients—either Frialit-2 (step screw; Friatec, Mannheim, Germany) or Camlog implants (root-form implants; Alltec, Wurmsberg, Germany) at least 13 mm long and 3.3 to 5.5 mm in diameter. Implants were placed using a 2-stage procedure either early (6 to 8 weeks after extraction) or late; a healing time of 6 to 9 months was accomplished, as described in previous studies.¹⁴⁻¹⁷

Sinus Augmentation Procedures

The sinus augmentation procedure recommended depended on the vertical dimension of the residual bone between the alveolar crest and the maxillary sinus floor (Fig 1). Selection of the appropriate surgical procedure was also influenced by the crown and implant lengths needed to achieve an implant-crown ratio greater than 1.0. Either the 1- or 2-stage lateral approach antrostomy technique or the crestal approach using the osteotome technique was used. The 2-stage approach was chosen when residual bone height was ≤ 5 mm. The 1-stage technique was used only when residual bone was greater than 5 mm and primary implant stability was achieved. For both lateral approaches (1-stage or 2-stage), antrostomy of the maxillary sinus was done without preparing a facial bone lid (hinge door). Only a round access hole was prepared in the maxillary facial wall extending to (but not disturbing) the adjacent roots. The sinus membrane was elevated in traditional fashion to permit placement of a 15- to 16-mm-long implant (Fig 2a). Because of the smallness of the access hole, tearing of the sinus membrane was considered an intraoperative surgical complication and was compared

Fig 2 (a) Antrostomy access after dissection and elevation of the sinus membrane. (b) Bone graft was condensed around the implant body, filling the buccal window.

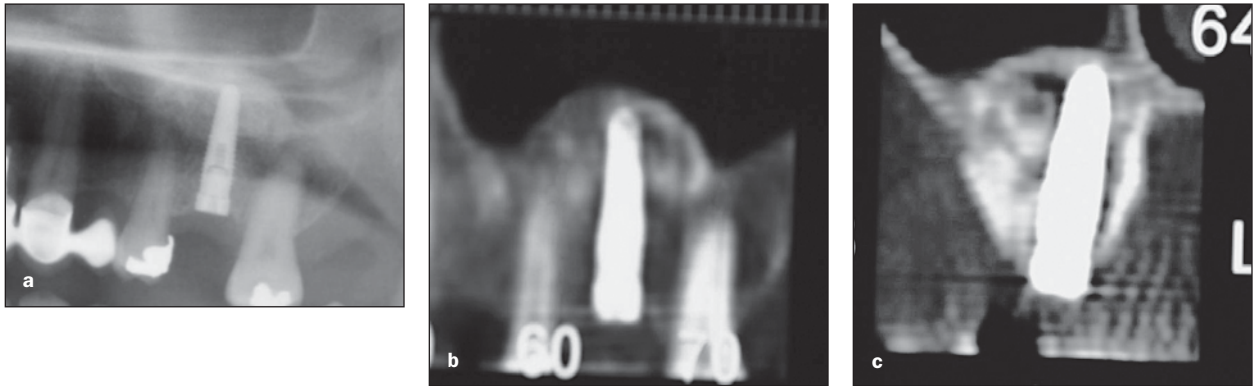
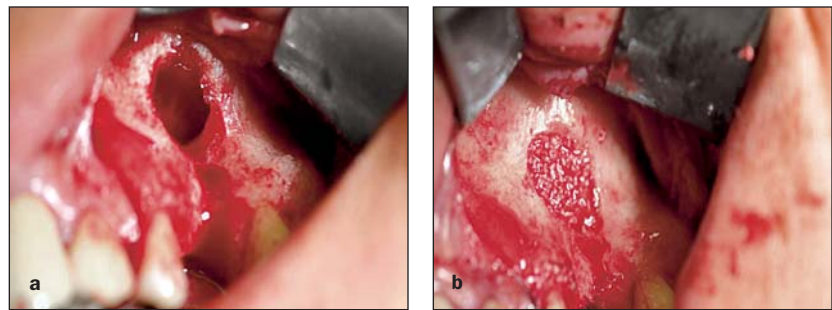


Fig 3 (a) Postoperative panoramic radiograph showing a root-form implant (Camlog) in the augmented sinus. (b and c) Postoperative panoramic and cross-sectional CT scans showing supporting bone around the implant in the augmented sinus.

between the 1- and 2-stage procedures. The elevated area of the maxillary sinus was filled with a mixture of autogenous bone graft (harvested from the maxillary tuberosity and/or using collected bone particles from drilling) and Bio-Oss (Geistlich, Wolhusen, Switzerland; Fig 2b). The lateral access window was covered with a bioresorbable collagen membrane (Bio-Gide; Geistlich). Healing time varied between 6 and 9 months, depending on the type of procedure (1- or 2-stage) and on the augmentation volume. Postoperative radiography of the maxilla (orthopantomogram, computerized tomographic [CT] panoramic and cross-sectional scans) is shown in Fig 3.

The osteotome technique was used when only a small amount of augmentation (≤ 3 mm of vertical height) was necessary to place implants of the length desired. Sinus membrane perforation was evaluated by manual testing and the Valsalva pressure test. For the osteotome technique apical augmentation was carried out using Bio-Oss alone. A healing time of 6 months was required.

Follow-up

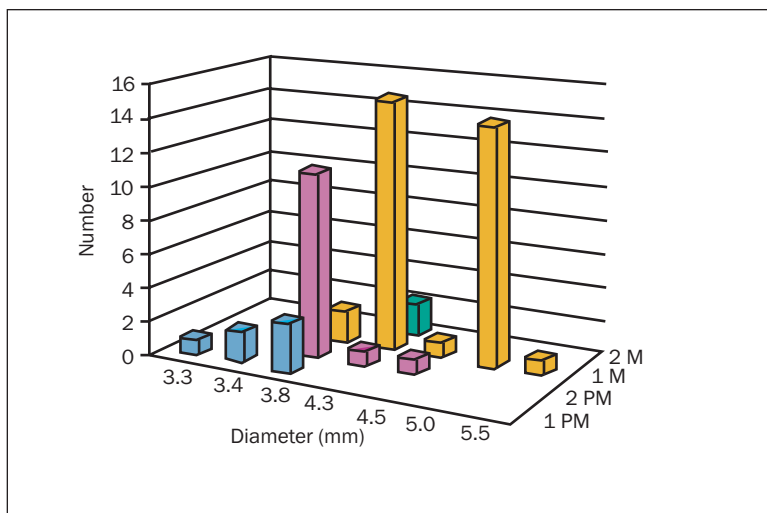
All patients included were part of a regular recall program. They were initially evaluated at intervals of 3 to 6 months for the first year and annually thereafter. The

recall program included assessments of peri-implant marginal bone loss (mm), pocket depth (mm), the Plaque and Gingival Indices (grade of 0 to 3), implant mobility (Periotest; Siemens, Bensheim, Germany), and implant survival time (in months), as described in previous studies.²³⁻²⁵ Marginal bone resorption for the implants was assessed radiographically using the method of Gomez-Roman et al.²⁶ The radiographic evaluation included an orthopantomogram and/or single periapical radiographs using the paralleling technique. The initial postoperative radiograph was compared with the most recent one. Mesial, distal, lingual, and buccal pocket depth were measured using a calibrated periodontal probe (Hu-Friedy, Chicago, IL). For all implants, the implant mobility was measured with the Periotest at the abutment close to the implant edge when the prostheses were removed for cleaning or for checking of the abutment screws during at least 1 postplacement examination.

At the last follow-up, prosthodontic complications were assessed. All clinical data were obtained to evaluate the results of single-tooth implants placed in augmented maxillary sinuses at least 2 years after the completion of prosthetic treatment. Evaluated parameters were described and compared for the different surgical procedures.

Table 1 Patient Characteristics, Implant Length, Intended Prosthetic Crown Length, Implant-Crown Ratio, and Residual Ridge Height by Sinus Augmentation Procedure

| Sinus lift technique | Patients | | | | Implant length* (mm) | Crown length* (mm) | Implant-crown ratio* | Residual ridge height* (mm) |
|----------------------|----------|------|-------|----------|----------------------|--------------------|----------------------|-----------------------------|
| | Female | Male | Total | Implants | | | | |
| 1-stage antrostomy | 15 | 10 | 25 | 28 | 15.6 ± 0.3 | 11.6 ± 1.3 | 1.36 ± 0.14 | 7.8 ± 0.8 |
| 2-stage antrostomy | 6 | 6 | 12 | 12 | 16.0 | 12.0 ± 1.0 | 1.33 ± 0.11 | 3.5 ± 0.8 |
| Osteotome technique | 11 | 3 | 14 | 14 | 14.7 ± 1.3 | 11.6 ± 1.1 | 1.21 ± 0.12 | 9.6 ± 0.9 |
| Total | 32 | 19 | 51 | 54 | 15.4 ± 0.5 | 11.7 ± 1.1 | 1.31 ± 0.12 | 6.7 ± 0.9 |

**Fig 4** Distribution of implants according to implant diameter and jaw regions. 1 PM = first premolar; 2 PM = second premolar; 1 M = first molar; 2 M = second molar.

Statistical Analysis

The parameters were recorded, tabulated, and evaluated using descriptive statistics. Mean values were compared using the Student *t* test, nonparametric data using the χ^2 test. $P < .05$ was considered indicative of statistical significance.

RESULTS

A total of 54 single implant-supported restorations were placed in 51 patients (32 female and 19 male; mean age, 51.6 ± 12.9 y; range, 29 to 86 y) in isolated grafted maxillary sinus sites. The 54 implants included 11 early and 43 late implants, 10 Frialit-2 implants, and 44 Camlog root-form implants. The 1-stage sinus lift group comprised 25 patients (mean age, 48.3 ± 12.1 y; range, 37 to 66 y) with 28 implants; the 2-stage sinus lift group, 12 patients (mean age: 53.8 ± 8.6 y; range, 42 to 66 y) with 12 implants; and the osteotome group, 14 patients (mean age: 54.6 ± 17.3 y; range, 29 to 86 y) with 14 implants. For all patients the intended implant crown had a mean length of 11.7 ± 1.1 mm (range, 9.5 to 14 mm; Table 1). Thus, all implants placed had a length of at least 13 mm to achieve an implant-crown ratio ≥ 1.0. All implants placed in the

1- or 2-stage antrostomy sinus elevation procedure had maximal length (15 or 16 mm), while the implants placed in conjunction with the osteotome technique were shorter (13 mm; Table 1).

Table 1 summarizes patient characteristics, implant length, prosthetic crown length, residual ridge height, and implant-crown ratio according to the different sinus augmentation procedures performed. The osteotome group demonstrated significantly greater ($P < .01$) presurgical bone height (9.6 ± 0.9 mm) than the 1-stage antrostomy group (7.8 ± 1.1 mm) or the 2-stage antrostomy group (3.5 ± 0.8 mm).

Figure 4 shows the distribution of the implants by diameter and location. More implants ($n = 33$; 61%) were placed in the first molar area than in the first and second premolar regions ($n = 6$ and $n = 13$, respectively, or 11% and 24%) or the second molar region ($n = 2$; 4%). Seventeen of 19 (89.5%) implants replacing premolar teeth had a regular (3.8 mm) or reduced (3.3 to 3.8 mm) diameter, but 33 of 35 implants in the molar region (94.4%) had a diameter of 4.3 to 5.5 mm. Only 7 implants (13%) were placed as terminal abutments, while significantly more implants ($n = 47$, 87%) were placed between 2 existing teeth ($P < .01$).

Table 2 Clinical Parameters of Single-Tooth Implants (n = 54) in Relation to Sinus Augmentation Procedure

| | Bone resorption | | Pocket depth | | Periotest | |
|---------------------|-----------------|------------|--------------|------------|-------------|----------|
| | Mean ± SD | Range | Mean ± SD | Range | Mean ± SD | Range |
| 1-stage antrostomy | 2.2 ± 1.4 | 1.0 to 3.5 | 3.6 ± 1.6 | 1.0 to 5.0 | -3.6 ± -1.2 | -2 to -5 |
| 2-stage antrostomy | 2.1 ± 1.3 | 0.5 to 3.5 | 3.4 ± 1.8 | 1.0 to 6.0 | -3.2 ± -1.6 | -2 to -6 |
| Osteotome technique | 2.3 ± 1.2 | 1.0 to 3.0 | 3.4 ± 1.6 | 1.0 to 1.5 | -3.8 ± -1.3 | -2 to -5 |
| Total | 2.2 ± 1.4 | 0.5 to 3.5 | 3.6 ± 1.8 | 1.0 to 6.0 | -3.6 ± -1.5 | -2 to -6 |

All implants in the antrostomy groups were the maximum length available (15 mm for Frialit-2 and 16 mm for Camlog). A mean implant-crown ratio of 1.36 ± 0.14 (range, 1.07 to 1.68) was achieved for these groups. Because implants with a length of 13 mm (n = 5) were only used in the group with osteotome technique (n = 14), this group had a smaller implant-crown ratio (mean, 1.21 ± 0.12 ; range, 1.08 to 1.45; $P > .05$).

Perforation of the sinus membrane was an intra-operative complication in 23 of 40 cases (58%) augmented with 1- or 2-stage antrostomy, with no difference for the incidence of this complication between the use of a 1-stage (16 of 28; 57%) or 2-stage procedure (7 of 12; 58%). In all cases, sinus membrane perforation could be repaired using a collagen membrane (Bio-Gide) in combination with blood clotting or fibrin glue. A lower incidence of (suspected) membrane perforation was seen with the osteotome technique (3 of 14, 21%), although suspected perforations without clinical verification may not always have been noted.

There were no dropouts, and all implants were followed for a mean of 44.5 ± 22.7 months (at least 2 years). At the time of the last follow-up, all implants followed were successfully integrated, representing a survival rate of 100%. In all cases, implants were restored with cement-retained porcelain-fused-to-metal crowns. Peri-implant conditions such as radiographic marginal bone resorption, pocket depth, and Periotest values of all implants followed and evaluated at the last examination have been summarized in Table 2. There were no differences in peri-implant parameters (peri-implant soft tissue conditions [Plaque Index: grade 0, 79%; grade 1, 19%, grade 2, 2%; Gingival Index: grade 0, 89%; grade 1, 11%], stability, marginal bone resorption, and pocket depth) among the 3 sinus augmentation procedures. The prosthodontic follow-up showed only minor complications: crown loosening as a result of cement washout (n = 4; 7.4%); abutment-screw loosening (n = 3; 5.5%), and porcelain fracture (n = 2; 3.7%).

DISCUSSION

Maxillary sinus augmentation has become a predictable and successful treatment procedure for dental implant placement in atrophic posterior regions.³⁻⁵ Numerous studies have reported high success rates for dental implants used for different prosthodontic rehabilitation modalities after sinus augmentation procedures.⁶⁻¹² In addition, single-tooth implant rehabilitation has also provided for a high success rate.¹⁴⁻¹⁹ Results of studies of single implant-supported restorations demonstrate successful implant stability and excellent soft tissue conditions, and in most cases these restorations also fulfill patients' and clinicians' requirements for optimal esthetic and functional outcome.¹⁷⁻²⁰ However, the literature includes few reports in which the combined use of these procedures (sinus elevation in conjunction with single implant-supported restoration) is described in detail. Reports on single implant-supported restorations only describe a small number of single-tooth implants placed in augmented maxillary areas.^{14,16,17} The predominant maxillary augmentation area investigated and described for single implant-supported restorations is the maxillary anterior esthetic zone, where different methods of bone grafting have been used.^{27,28} Corticocancellous bone onlay grafts or guided bone regeneration techniques using several graft materials have been described in detail and are associated with high implant success rates and esthetic success.²⁷⁻³¹

When single implant-supported restorations in regions where sinus augmentation has been performed are discussed in reports, they are mostly discussed as part of a comprehensive single-tooth implant study.¹⁴⁻¹⁹ In contrast to studies reporting on augmentation in anterior maxillary regions, results for single implant-supported restorations placed in augmented posterior maxillary regions have rarely been published. Only 1 previous study could be found, a report by Mazor et al²² of the results of 10 single-tooth implants placed in augmented sinus sites.

The findings of the present study provide detailed information on outcome of single implant-supported restorations placed in the augmented posterior maxillary sinus. Furthermore, the peri-implant conditions of implants placed with different sinus elevation procedures were compared. Optimum implant and crown lengths were planned to achieve a sufficient (> 1.0) implant-crown ratio to withstand the vertical and lateral occlusal forces expected in this region.^{19,31-33} An implant-crown ratio > 1.0 and a wider diameter in optimal relation increase the ability of the restoration to absorb loading forces, especially in molar sites, and thus enhances the survival of single-tooth implants, as described in previous studies.¹⁹ Ante's law³² and reports of previous investigations in conventional prosthetic dentistry describe the importance of the root-crown ratio for the success of traditional prosthodontic rehabilitation.^{32,33} Similarly, a favorable implant length and implant-crown ratio may have also had a beneficial effect on the predictability of osseointegration and thus on the success rate of single-implant restorations.¹⁶⁻¹⁸

In contrast to studies of multiple-implant rehabilitation, implant failures in studies of single-tooth implants have been generally limited to isolated cases, and the implants lost have typically been short.¹⁴⁻¹⁷ Haas et al¹⁶ and Priest³⁴ both reported the loss of implants 10 mm in length; furthermore, 2 of the 3 single-tooth implants lost in a study by Jemt et al³⁵ were relatively short (lengths of 10 mm and 7 mm). The impact of implant length on implant prognosis was described by Ferrigno et al³⁶ as well as by Herrmann et al.³⁷ They reported that maxillary implants longer than 10 mm have a better prognosis than those that are 10 mm or shorter. These data may be confirmed by the results of the present study, in which a survival rate of 100% was observed after more than 2 years of loading. The predominant use of long and wide implants in the maxillary molar area may provide for an optimal implant-crown ratio, which may improve long-term success without complications.^{3,19,36-38}

In the present study, the osteotome technique was used even in cases where shorter implants could have been placed without augmentation to enable the placement of implants of the desired length and achieve a desirable implant-crown ratio. This is in contrast to recent reports describing successful results with short implants or reduced implant-crown ratios.³⁹⁻⁴² The positive effect of criteria used for implant length and implant-crown ratio on the long-term results justifies the use of the osteotome technique in single-tooth implants.^{12,36,43}

The findings of the present study demonstrate that the implant survival rate did not differ between the 1-stage lateral approach, the 2-stage lateral approach, and the crestal approach. The survival rate for the present study was comparable to that reported for other single-tooth implant studies.^{12,16-19} However, regarding the survival rate for single implants in the augmented sinus, it must also be considered that in this study nearly 90% of the implants placed had pre-existing adjacent dentition bilaterally. Surrounding dentition and the possibility of reduced occlusal loading of the single implants in the augmented regions may represent a protective factor for single-tooth implants in posterior regions and may be beneficial for the long-term success of single-tooth implants placed with sinus augmentation.

No differences in measures of success such as the Plaque Index, Gingival Index, pocket depth, and implant stability were observed between the augmentation procedures performed. This confirms previously reported results on different sinus lift augmentation procedures as well as the results of several single-tooth implant studies.^{1,4-9,12-17} The minor peri-implant marginal bone resorption encountered must be considered as development within the biologic band width; no difference in peri-implant bone resorption was observed between the various augmentation procedures.^{44,45}

The incidence of intraoperative complications (ie, perforation of the sinus membrane) in the antrostomy groups was significantly higher than that generally reported for sinus augmentation procedures in edentulous maxillary regions.^{2,46-48} The results of the present study are in accordance with results of Mazar et al.²² The high incidence of intraoperative complications may have been due to the restriction of the access area. The antrostomy was of necessity small; adjacent root apices precluded the possibility of mesial or distal extension, which may have caused tearing of the membrane more frequently.²² All membrane perforations were successfully repaired using collagen membrane and showed uneventful healing, with normal implant placement and prosthodontic rehabilitation.⁴⁸

When the patient must choose between a single implant-supported restoration or fixed partial dentures, especially in cases with insufficient bone volume for implant placement,⁴⁹⁻⁵¹ the conflict between clinical and economic aspects of the treatments often creates a dilemma. However, as shown by the results of the current study, the procedure described, when performed in accordance with the recommendations for surgical and implant characteristics, is a valid treatment option, provided patient collaboration and patience can be assured.

CONCLUSION

On the basis of this retrospective clinical review, the following was observed:

1. Successful function and excellent peri-implant parameters may be anticipated for single implant-supported restorations placed in conjunction with different sinus elevation procedures.
2. Clinical and radiographic examinations demonstrated similar conditions for single implant-supported restorations despite the use of different surgical approaches to sinus augmentation.

REFERENCES

1. van den Bergh JP, ten Bruggenkate CM, Disch FJ, Tuinzing DB. Anatomical aspects of sinus floor elevations. *Clin Oral Implants Res* 2000;11:256–165.
2. Garg AK. Augmentation grafting of the maxillary sinus for placement of dental implants: anatomy, physiology, and procedures. *Implant Dent* 1999;8:36–46.
3. Boyne PJ, James RA. Grafting of the maxillary sinus floor with autogenous marrow and bone. *J Oral Surg* 1980;38:613–616.
4. Wallace SS, Froum SJ. Effect of maxillary sinus augmentation on the survival of endosseous dental implants. A systematic review. *Ann Periodontol* 2003;8:328–343.
5. Chanavaz M. Sinus grafting related to implantology. Statistical analysis of 15 years of surgical experience (1979–1994). *J Oral Implantol* 1996;22:119–130.
6. Hallman M, Nordin T. Sinus floor augmentation with bovine hydroxyapatite mixed with fibrin glue and later placement of nonsubmerged implants: A retrospective study in 50 patients. *Int J Oral Maxillofac Implants* 2004;19:222–227.
7. Valentini P, Abensur DJ. Maxillary sinus grafting with anorganic bovine bone: A clinical report of long-term results. *Int J Oral Maxillofac Implants* 2003;18:556–560.
8. Stricker A, Voss PJ, Gutwald R, Schramm A, Schmelzeisen R. Maxillary sinus floor augmentation with autogenous bone grafts to enable placement of SLA-surfaced implants: Preliminary results after 15–40 months. *Clin Oral Implants Res* 2003;14:207–212.
9. Zitzmann N, Schaerer PO. Sinus elevation procedures in the resorbed maxilla. Comparison of the crestal and lateral approach. *Oral Surg Oral Med Oral Pathol Oral Radiol Endod* 1998;85:8–17.
10. Summers RB. A new concept in maxillary implant surgery: The osteotome technique. *Compend Contin Educ Dent* 1994;15:152–160.
11. Toffler M. Osteotome-mediated sinus floor elevation: A clinical report. *Int J Oral Maxillofac Implants* 2004;19:266–273.
12. Rodoni LR, Glauser R, Feloutzis A, Hammerle CH. Implants in the posterior maxilla: A comparative clinical and radiologic study. *Int J Oral Maxillofac Implants* 2005;20:231–237.
13. Leblebicioglu B, Ersanli S, Karabuda C, Tosun T, Gokdeniz H. Radiographic evaluation of dental implants placed using an osteotome technique. *J Periodontol* 2005;76:385–390.
14. Engquist B, Nilson H, Astrand P. Single-tooth replacement by osseointegrated Brånemark implants. A retrospective study of 82 implants. *Clin Oral Implants Res* 1995;6:238–245.
15. Scholander S. A retrospective evaluation of 259 single tooth replacements by the use of Brånemark implants. *Int J Prosthodont* 1999;12:483–491.
16. Haas R, Polak C, Fürhauser R, Mailath-Pokorny G, Dortbudak O, Watzek G. A long-term follow up of 76 Brånemark single-tooth implants. *Clin Oral Implants Res* 2002;13:38–43.
17. Krennmair G, Schmidinger S, Waldenberger O. Single-tooth replacement with the Frialit-2 system. A retrospective clinical analysis of 146 implants. *Int J Oral Maxillofac Implants* 2002;17:78–85.
18. Higginbottom F, Belser U, Jones JD, Keith SE. Prosthetic management of implants in the esthetic zone. *Int J Oral Maxillofac Implants* 2004;19(suppl):62–72.
19. Belser U, Schmid B, Higginbottom F, Buser D. Outcome analysis of implants restorations located in the anterior maxilla: A review of the recent literature. *Int J Oral Maxillofac Implants* 2004;19(suppl):30–42.
20. Carrion JB, Barbosa IR. Single implant-supported restorations in the anterior maxilla. *Int J Periodontics Resorative Dent* 2005;25:149–155.
21. Holst S, Blatz MB, Hegenbarth E, Wichmann M, Eitner S. Prosthodontic considerations for predictable single-implant esthetics in the anterior maxilla. *J Oral Maxillofac Surg* 2005;63:89–96.
22. Mazor Z, Peleg M, Gross M. Sinus augmentation for single-tooth replacement in the posterior maxilla: A 3-year follow-up clinical report. *Int J Oral Maxillofac Implants* 1999;14:55–60.
23. Aparicio C. The use of the Periotest value as the initial success criteria of an implant: 8-year report. *Int J Periodontics Restorative Dent* 1997;17:150–161.
24. Silness J, Løe H. Periodontal disease in pregnancy II. Correlation between oral hygiene and periodontal conditions. *Acta Odontol Scand* 1964;22:121–135.
25. Quigley GA, Hein JW. Comparative cleansing efficiency of manual and power brushing. *J Am Dent Assoc* 1962;65:26–29.
26. Gomez-Roman G, Axmann D, d'Hoedt B, Schulte W. Eine Methode zur quantitativen Erfassung und statistischen Auswertung des periimplantären Knochenabbaues. *Stomatologie* 1995;92:463–471.
27. Widmark G, Andersson B, Ivanoff CJ. Mandibular bone graft in the anterior maxilla for single-tooth implants. Presentation of surgical method. *Int J Oral Maxillofac Surg* 1997;26:106–109.
28. McCarthy C, Patel RR, Wragg PF, Brook IM. Dental implants and onlay bone grafts in the anterior maxilla: Analysis of clinical outcome. *Int J Oral Maxillofac Implants* 2003;18:238–241.
29. Kaufman E, Wang PD. Localized vertical maxillary ridge augmentation using symphyseal bone cores: A technique and case report. *Int J Oral Maxillofac Implants* 2003;18:293–298.
30. Raghoobar GM, Batenburg RHK, Vissink A, Reintsema H. Augmentation of localized defects of the anterior maxillary ridge with autogenous bone before insertion of implants. *J Oral Maxillofac Surg* 1996;54:1180–1185.
31. Yeung R. Simultaneous placement of implant and bone graft in the anterior maxilla: A case report. *Int J Oral Maxillofac Implants* 2004;19:892–895.
32. Ante IH. The fundamental principles of abutments. *Mich Dent Soc Bull* 1926;8:14.
33. Penny RE, Kraal JH. Crown-to-root ratio: Its significance in restorative dentistry. *J Prosthet Dent* 1979;42:34–38.
34. Priest G. Single-tooth implants and their role in preserving remaining teeth: A 10-year survival study. *Int J Oral Maxillofac Implants* 1999;14:181–188.
35. Jemt T, Laney WR, Harris D, et al. A 1-year report from a multi-center prospective study. *Int J Oral Maxillofac Implants* 1991;6:29–36.

36. Ferrigno N, Laureti M, Fanali S. Dental implants placement in conjunction with osteotome sinus floor elevation: A 12-year life-table analysis from a prospective study on 588 ITI implants. *Clin Oral Implants Res* 2006;17:194–205 [erratum 2006;17:479].
37. Herrmann I, Lekholm U, Holm S, Kultje C. Evaluation of patients and implant characteristics as potential prognostic factors for oral implant failures. *Int J Oral Maxillofac Implants* 2005;20:220–230.
38. Krennmair G, Waldenberger O. Clinical analysis of wide-diameter Frialit-2 implants. *Int J Oral Maxillofac Implants* 2004;19:710–715.
39. Winkler S, Morris HF, Ochi S. Implant survival to 36 months as related to length and diameter. *Ann Periodontol* 2000;5:22–31.
40. Hagi D, Deporter DA, Pilliar RM, Arenovich T. A targeted review of study outcomes with short (> or = 7 mm) endosseous dental implants placed in partially edentulous patients. *J Periodontol* 2004;75:798–804.
41. Deporter DA, Caudry S, Kermalli J, Adegbembo A. Further data on the predictability of the indirect sinus elevation procedure used with short, sintered, porous-surfaced dental implants. *Int J Periodontics Resorative Dent* 2005;25:585–593.
42. Renouard F, Nisand D. Short implants in the severely resorbed maxilla: A 2-year retrospective clinical study. *Clin Implant Dent Relat Res* 2005;7(suppl):104–110.
43. Rokni S, Todescan R, Watson P, Pharoah M, Adegbembo AO, Deporter DA. An assessment of crown-to-root ratio with short sintered porous-surfaced implants supporting prostheses in partially edentulous patients. *Int J Oral Maxillofac Implants* 2005;20:69–76.
44. Hartman GA, Cochran DL. Initial implant position determines the magnitude of crestal bone remodeling. *J Periodontol* 2004;75:572–577.
45. Hermann JS, Buser D, Schenk RK, Schoolfield JD, Cochran DL. Biologic width around one- and two-piece titanium implants. *Clin Oral Implants Res* 2001;12:559–571.
46. Misch CE. The maxillary sinus lift and sinus graft surgery. In: Misch CE. *Contemporary Implant Dentistry*. St Louis: Mosby, 1999:469–495.
47. Schwartz-Arad D, Herzberg R, Dolev E. The prevalence of surgical complications of the sinus graft procedure and their impact on implant survival. *J Periodontol* 2004;75:511–516.
48. Proussaefs P, Lozada J, Kim J, Rohrer MD. Repair of the perforated sinus membrane with a resorbable collagen membrane: A human study. *Int J Oral Maxillofac Implants* 2004;19:413–420.
49. Bahat O. Treatment planning and placement of implants in the posterior maxillae: Report of 732 consecutive Noblepharma implants. *Int J Oral Maxillofac Implants* 1993;8:151–161.
50. Brägger U, Krenander P, Lang NP. Economic aspects of single tooth replacement. *Clin Oral Implants Res* 2005;16:335–341.
51. Scurria MS, Bader JD, Shiugars DA. Meta-analysis of fixed partial denture survival: Prostheses and abutments. *J Prosthet Dent* 1998;79:459–464.