

One-year Follow-up of First Consecutive 100 Zirconia Dental Implants in Humans: A Comparison of 2 Different Rough Surfaces

Josep Oliva, MSc^{1,2}/Xavi Oliva, MSc¹/Josep D. Oliva, MD¹

Purpose: The aim of this study was to evaluate the success rate of 100 consecutive zirconia dental implants with 2 different rough surfaces after 1 year of follow-up. **Materials and Methods:** One-piece zirconia dental implants (CeraRoot, Barcelona, Spain) with 1 of 2 different roughened surfaces were designed and manufactured for this study. Five different implant designs were manufactured. Standard or flapless surgical procedures were used for implant placement. Simultaneous bone augmentation or sinus elevation were performed in the cases where bone height or width was insufficient. Implants in the anterior region (canine to canine) were immediately restored with provisional prostheses. Implants placed using less than 35 N torque were splinted with composite resin using an etched and bonded approach to the neighboring teeth or implants to minimize implant mobility and failure. Definitive all-ceramic restorations were placed 4 months after implant placement (8 months for implants where bone augmentation or sinus elevation was performed). **Results:** The study included 36 patients with a mean age of 50 years. The overall implant success rate after 1 year of follow-up was 98% in both the coated and noncoated groups. **Conclusions:** From the preliminary results of this investigation, it can be concluded that zirconia dental implants with roughened surfaces might be a viable alternative for tooth replacement. Further follow-up is needed to evaluate the long-term success rates of the implant surfaces studied. (Case Series) *INT J ORAL MAXILLOFAC IMPLANTS* 2007;22:430-435

Key words: bioceramic, ceramic, coatings, dental implants, rough surface, rough topography, zirconia, zirconium oxide

The material of choice for dental implants is commercially pure titanium, because it has well-documented biocompatibility and suitability for tooling. This biocompatible material¹ has been used for about 30 years as an implant substrate with high success rates.² One drawback from an esthetic point of view is that the dark color of titanium can shine through the thin mucosa.^{3,4} Furthermore, soft tissue shrinkage, recessions, and peri-implant lesions may leave the implant head visible. Although titanium is highly resistant to corrosion,² some investigations

have shown increased titanium concentration in bone near titanium implants⁵ and in regional lymph nodes, although the clinical relevance of these findings is not yet clear.⁶

One possible solution to the aforementioned problems with titanium would be to make implants from tooth-colored materials such as ceramics. All-ceramic materials are highly biocompatible.⁷ One ceramic material from which dental implants have been made is aluminum oxide (Al₂O₃). This implant, also known as the Tübingen implant (Frialit I), osseointegrated well.^{8,9} However, it did not have sufficient mechanical properties for long-term loading and was withdrawn from the market. There is a lack of published scientific data related to this product.


Recently, another ceramic material with potential for future use as in dental implants was introduced. Zirconia possesses good physical properties for use as a metal substitute. It has a high flexural strength (900 to 1,200 MPa), good hardness (1,200 Vickers),

¹Private Practice, Granollers, Barcelona, Spain.

²Department of Periodontology, Master of Periodontics, University of Barcelona, Spain.

Correspondence to: Dr Josep Oliva, 126 Josep Umbert, 08400 Granollers, Barcelona, Spain. Fax: +34 938792373. E-mail: laclinica@clinicaoliva.com

Fig 1 Surface topographies of the (left) noncoated and (right) coated implants.



and a Weibull modulus of 10 to 12.¹⁰⁻¹² Furthermore, its biocompatibility as a dental implant material has been demonstrated in several animal investigations.¹³⁻²⁰ In vitro simulations showed that the material appears to be capable of withstanding loads over the long term.¹⁷

Studies have shown that a rough surface topography enhances the bone integration process,²¹ but the turning of zirconia rods results in a relatively smooth surface. Sennerby et al²⁰ demonstrated higher removal torques at implant retrieval for porous zirconia surfaces in rabbits. However, no clinical studies comparing zirconia implants with different surface topographies have been published.

The aim of the present investigation was to evaluate the 1-year success rate of 100 consecutive zirconia implants with 2 different surface roughnesses in humans.

MATERIALS AND METHODS

All patients between 19 and 80 years old who were in need of tooth replacement were included in this study except for smokers and patients with a health condition or disease that might contraindicate an oral surgery, including pregnancy and breastfeeding.

One-piece zirconia dental implants with 2 different rough surfaces were specially designed and manufactured for this study (50 of each surface). The fabrication process consisted of pressing cold zirconia powder (TZ-3YSB-E; Tosoh Corporation, Tokyo, Japan) into rods. Rods were presintered and then turned into threaded implants. Two different treatments were used to achieve a porous surface. In 1 group, the noncoated group, a special diamond wheel was used to mechanically roughen the surface. In the other group, the coated group, the implants were coated with a stable bioactive ceramic material with the following composition: Na₂O-K₂O-MgO-Al₂O₃-CaO-SiO₂-P₂O₅-F. After the roughening process, the implants were sintered to full density.

An interferometer was used to characterize the surface topography using the following parameters:

Table 1 Surface Topography Characterization

| Group/ surface area | Rp-v (nm) | Ra (nm) | RMS (nm) |
|------------------------|-----------|---------|----------|
| Coated group | | | |
| 225 μm ² | 3110 | 436 | 367 |
| 25 μm ² | 710 | 91.9 | 72.6 |
| Noncoated group | | | |
| 225 μm ² | 1450 | 293 | 231 |
| 25 μm ² | 370 | 63.5 | 52.1 |

(1) Average roughness (Ra), defined as the average distance from the profile to mean line over the length of the assessment; (2) roughness peak to valley (Rp-v), described as the vertical distance between the highest and lowest points of the surface; and (3) root mean square (RMS), defined as the average between the height deviations and the mean surface height. In summary, the coated implants showed greater surface roughness (Table 1, Fig 1).

Five different designs of implants were manufactured for different indications (Fig 2). Each type of implant was designed to create a toothlike emergence profile for the prosthetic restoration. These 1-piece implants had 3 distinct areas: (1) the threaded endosseous area, which had a roughened surface; (2) the transmucosal part, which helps establish the emergence profile; and (3) the abutment, for seating of the prosthetic restoration.

Patients were alternately assigned to either the coated or noncoated group. All patients received information about zirconia implants and the possible alternatives, and all gave their written informed consent.

Panoramic radiographs and photographs were obtained preoperatively. Casts were made and in cases, and waxups were used to fabricate the surgical splint and to determine the best implant for use in each situation.

If possible, the implants were placed transmucosally using a flapless technique; otherwise, standard procedures for implantation were used. In cases where the implants were placed immediately after tooth extraction, no incisions, flaps, or sutures were

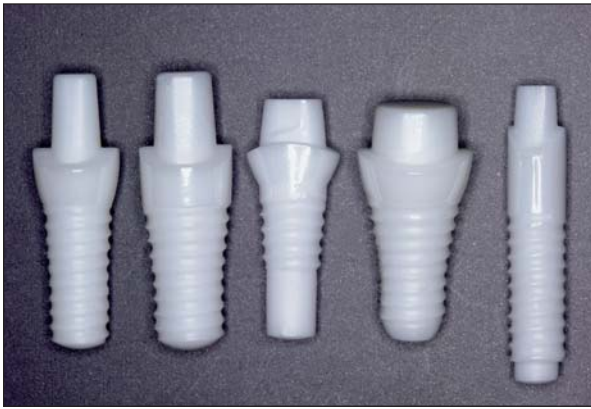

Fig 2 Implant designs used in the study. (Left to right) These implants were used in (1 and 2) the maxillary central incisal and canine regions, (3) the maxillary and mandibular premolar regions, (4) the maxillary and mandibular molar regions, and (5) the maxillary lateral incisal region (and mandibular incisal region).

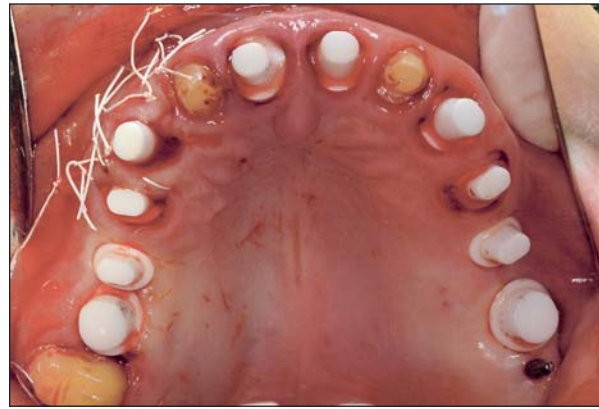

Fig 3 Zirconia implants were placed in immediate extraction sites without raising a flap in sites 5(14), 6(13), 8(11), 9(21), and 12(24). Implants were placed transmucosally in sites 3(16), 4(15), 13(25), and 14(26). In site 11(23), an implant was placed immediately postextraction; in this case, a flap was raised.

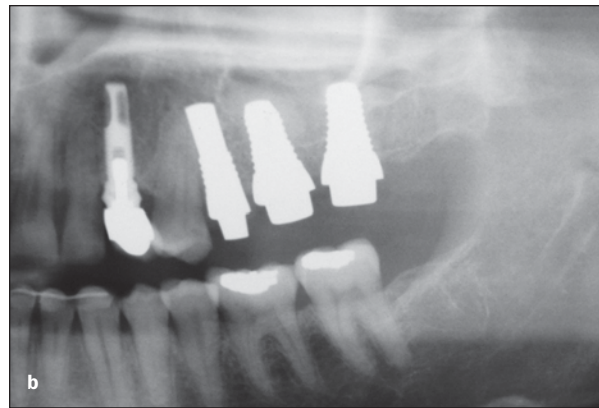
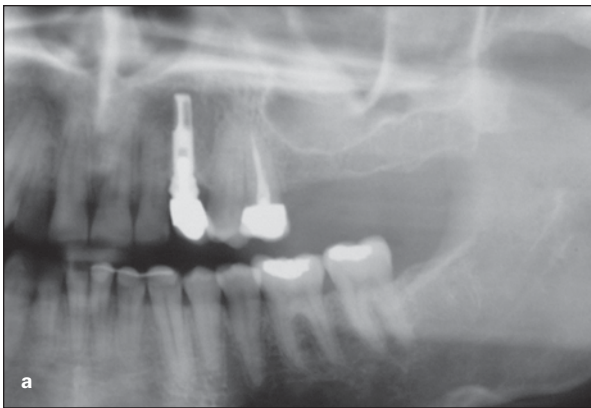


Fig 4 (a) A patient with a hopeless tooth 13(25) and insufficient bone height in teeth 14(26) and 15(27). (b) An implant was placed in site 13(25) immediately postextraction. Implants were placed in sites 14(26) and 15(27) together with a sinus elevation procedure. Autologous bone and demineralized freeze-dried bovine bone.

necessary. The implant sites were examined for bone fenestrations or dehiscences after site preparation; in cases where fenestrations or dehiscences were observed, a flap was raised and a bone regenerative procedure was performed (Fig 3).

Regenerative procedures were carried out in all sites with insufficient horizontal or vertical crestal bone with autologous or demineralized freeze-dried bovine bone. A surgical guide was used in all cases for the optimal positioning and inclination of the implants. The usual drill sequence was: first, round burs; second, twist drills; and finally, a countersink. In the mandible, when bone density was high, the implant site was pretapped to facilitate implant insertion into the bone. Panoramic radiographs were obtained immediately after surgery to verify implant positions.

Whenever the implants were placed in the esthetic zone (from canine to canine) using more than 35 Ncm of torque, the implants were immediately restored with a cemented provisional restoration placed slightly out of occlusion. Implants placed with lower insertion torque values received either a provisional restoration connected to neighboring teeth that also needed to be restored or were cemented to the neighboring teeth with a resin-based composite (Tetric Flow; Ivoclar Vivadent, Schaan, Liechtenstein) to minimize the risk of implant mobility and failure.

In the posterior maxilla, in patients with insufficient bone height (8 mm or less), sinus elevation and implant placement were carried out in a single surgery (Fig 4). If the residual crestal bone height was less than 5 mm, then the implants were splinted

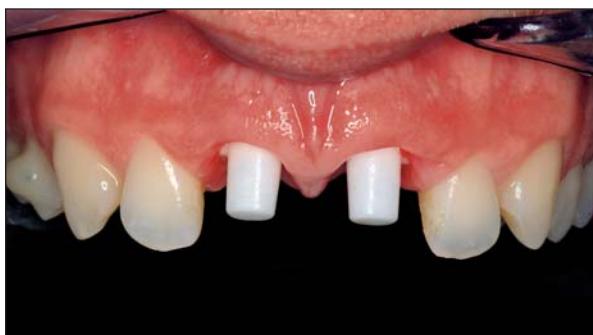
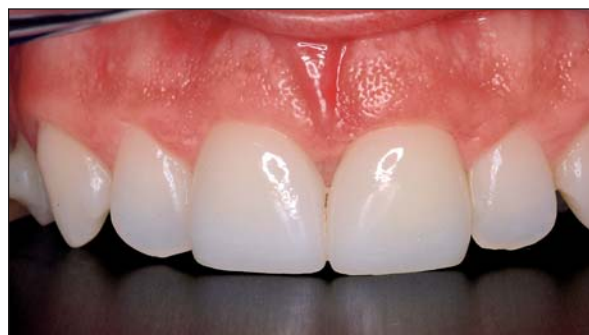
Fig 5 Placement of a definitive all-ceramic restoration. Note the color match with the neighboring teeth and the integration with the soft tissues.



together with the neighboring teeth or implants to avoid implant mobility and failure. Implants placed in the posterior maxilla using less than 35 N torque were also splinted together with the neighboring teeth with standard composite to minimize the risk of failure.

All patients received oral hygiene maintenance instructions and were advised not to use the implants for chewing or eating during the first 2 months after surgery. The patients were seen 15 days postsurgery for follow-up and suture removal. Implants were checked for mobility, pain, and probing depth once a month. Dental hygiene was performed whenever necessary to maintain a clean and disinfected mouth. Impressions were made 3 months postsurgery.

The definitive restoration was placed 4 months after surgery (Fig 5), except in cases where sinus grafting or bone regenerative procedures were performed. In these cases the implants were left to heal for 8 months before insertion of the definitive ceramic restoration. All the definitive restorations were left slightly in infraocclusion to compensate for the elasticity of the periodontal ligament of natural teeth. Contacts in the lateral excursions were avoided.

All-ceramic restorations were made through the use of a computer-aided design/computer-assisted manufacturing (CAD/CAM) system (LAVA; 3M/ESPE, St Paul, MN) or through the use of a pressed ceramic material (Empress II; Ivoclar Vivadent). Definitive cementation was performed with a glass ionomer cement (GC FujiCEM; GC America, Alsip, IL).

After delivery of the definitive restoration, the patients were followed up at 1, 3, 6, and 12 months. A panoramic and/or periapical radiograph was obtained at month 12 (Fig 6).

RESULTS

The study included 36 patients with a mean age of 50 years (range, 28 to 78 years) treated between Jan-

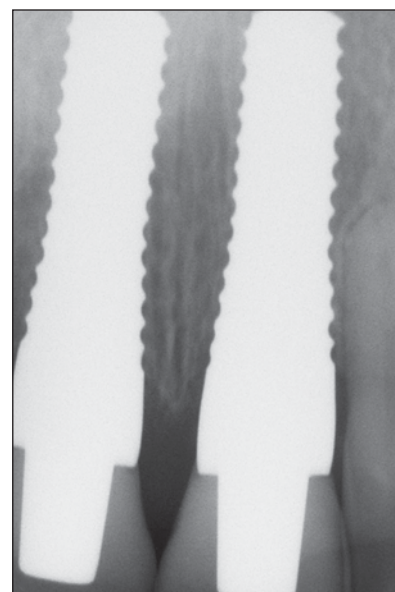


Fig 6 One-year follow-up of 2 maxillary central incisors. Note the fit of the restorations and the preservation of the interimplant crestal bone.

uary and December 2004. The patients were followed for a minimum of 1 year. The implants were placed in all regions of the mouth: 34 (17 coated and 17 noncoated) in the esthetic zone, 46 (23 coated and 23 noncoated) in the posterior maxilla (posterior to canines), 4 (2 coated and 2 noncoated) in the anterior mandible, and 16 (8 coated and 8 noncoated) in the posterior mandible.

Fifty implants (24 coated and 30 noncoated) were placed using a flapless technique (including immediate implants). Forty-one implants (21 coated and 20 noncoated) were immediately restored with a provisional prosthesis, 20 of which (10 coated and 10 noncoated) were splinted to neighboring teeth or implants. Thirty-three implants (16 coated and 17

noncoated) were placed in conjunction with bone grafting procedures. Sinus elevations were performed on 19 implants (10 coated and 9 noncoated).

Two implants (1 coated and 1 noncoated) failed 15 days postsurgery. In each case, the implant was placed simultaneous with sinus elevation in a male patient with less than 5 mm of residual crestal bone. In both cases the patient had broken the composite splint, and the implants were mobile. These implants were extracted, and the sinus graft was left to heal 8 months before implant placement was reattempted. No other implant failures were reported at any stage of the treatment or during the first year of follow-up. No problems regarding pain, inflammation, bleeding, or radiolucency were reported.

To be considered successful at the 1-year follow-up, implants had to be free of pain on percussion. There could be no bleeding on probing, signs of inflammation, mobility of implants or restorations, or radiolucency.

The overall implant success rate at the 1-year follow-up was 98% in both the coated and noncoated groups. The overall survival rate after the first month postsurgery was 100%.

DISCUSSION

Osseointegration of threaded zirconia implants has been demonstrated in various animal models. Akagawa et al¹⁴ compared the bone tissue response to loaded and unloaded zirconia implants in the dog mandible. The authors reported high degrees of bone-implant contact 3 months after implantation, with no significant differences between the groups. In a monkey model, Akagawa et al¹⁵ examined the possibility of long-term stability of osseointegration around partially stabilized zirconia implants placed in a 1-stage procedure with (1) single freestanding implant support, (2) connected freestanding implant support, or (3) a combination of implant and tooth support. No significant differences were observed among the different types of support. Direct bone apposition to the implant was generally seen in all groups. Histometrically, no significant differences were observed between the groups. No mechanical problems, such as implant fracture, were reported.

Kohal et al¹⁸ compared custom-made titanium and zirconia implants used to support metal crowns in the maxillae of 6 monkeys. Both types were sandblasted, and the titanium was also acid-etched. All implants achieved and maintained stability, and no mechanical problems were reported. Histology revealed no differences in the bone tissue response to the titanium and zirconia implants.

In another study, Kohal et al¹⁷ performed 3-dimensional computerized stress analysis of commercially pure titanium and yttrium-partially stabilized zirconia implants. They found very similar stress distributions for these implants and commercially pure titanium implants.

Sennerby et al²⁰ reported a study of surface-modified (ie, coated) zirconia implants on rabbits. A strong bone tissue response to surface-modified zirconia implants was observed after 6 weeks of healing. The modified zirconia implants showed a resistance to torque forces similar to that of oxidized implants, a 4- to 5-fold increase over that demonstrated for machined zirconia implants. The findings suggested that surface-modified zirconia implants can reach a firm stability in bone.

Other ceramics, such as aluminum oxides, have been used as dental implants. Clinical follow-up studies on the Tübingen^{8,9,22} implant showed survival rates of more than 90%. However, this implant was later withdrawn from the market, possibly owing to problems with mechanical failure.

Substantial evidence suggests that zirconia ceramics are highly biocompatible and have the mechanical properties required to serve well as materials for dental implants.¹³⁻²⁰ However, to the knowledge of the present authors, clinical experience with zirconia implants is very limited, and only a few case reports have been published. Kohal and Klaus²³ published one such case report. The authors extracted a hopeless maxillary central incisor and immediately implanted a zirconia implant. Graft material was also used to fill a bone defect at the site. After the bone had been allowed to heal for 6 months, an abutment was cemented onto the zirconia implant, and the definitive restoration was delivered. The final radiographic and esthetic outcomes were excellent.

The present article is the first to report on 100 zirconia dental implants with 2 different surface roughnesses in humans after 1 year of follow-up. The overall success rate was 98%, which is comparable with success rates reported for standard titanium implants. Considering that the only 2 failed implants were placed in situations where sinus elevation was required, future investigators may wish to exclude patients with less than 5 mm residual bone. More studies are needed to evaluate the long-term success rate of zirconia implants. Comparative studies of different kinds of zirconia and titanium implant surfaces are also needed.

CONCLUSIONS

From the preliminary results of this investigation, it can be concluded that zirconia dental implants with roughened surfaces might be a viable alternative for tooth replacement. Further follow-up is needed to evaluate the long-term success rates of the implant surfaces studied.

REFERENCES

1. Kasemo B, Lausmaa J. Biomaterial and implant surfaces: A surface science approach. *Int J Oral Maxillofac Implants* 1988;3:247–259.
2. Kasemo B, Lausmaa J. Biomaterials and interfaces. In: Naert I, van Steenberghe D, Worthington P (eds). *Osseointegration in Oral Rehabilitation*. London: Quintessence, 1993:63–75.
3. Heydecke G, Kohal R, Glaser R. Optimal esthetics in single-tooth replacement with the Re-Implant system: A case report. *Int J Prosthodont* 1999;12:184–189.
4. Wohlwend A, Studer S, Schärer P. The zirconium oxide abutment—A new all-ceramic concept for esthetically improving suprastructures in implantology [in German]. *Quintessenz Zahntech* 1996;22:364–381.
5. Bianco PD, Ducheyne P, Cuckler JM. Local accumulation of titanium released from a titanium implant in the absence of wear. *J Biomed Mater Res* 1996;31:227–234.
6. Weingart D, Steinemann S, Schilli W, et al. Titanium deposition in regional lymph nodes after insertion of titanium screw implants in maxillofacial region. *Int J Oral Maxillofac Surg* 1994;23:450–452.
7. Silva VV, Lameiras FS, Lobato ZI. Biological reactivity of zirconia-hydroxyapatite composites. *J Biomed Mater Res* 2002;63:583–590.
8. Schulte W. The intra-osseous Al₂O₃ (Frialit) Tübingen Implant. Developmental status after eight years (I-III). *Quintessence Int* 1984;15:1–39.
9. Schulte W, d'Hoedt B. Thirteen years of the Tübingen implant system made by Frialit—Additional results [in German]. *Z Zahnärztl Implantol* 1988;3:167–172.
10. Marx R. Modern ceramic materials for esthetic restorations—Strengthening and fracture toughness [in German]. *Dtsch Zahnärztl Z* 1993;48:229–236.
11. Piconi C, Burger W, Richter HG, et al. Y-TZP ceramics for artificial joint replacements. *Biomaterials* 1998;19:1489–1494.
12. Stevens R. *Zirconia and Zirconia Ceramics: An Introduction to Zirconia*, ed 2. Twickenham, UK: Litho 2000;1986:1–51.
13. Albrektsson T, Hansson HA, Ivarsson B. Interface analysis of titanium and zirconium bone implants. *Biomaterials* 1985;6:97–101.
14. Akagawa Y, Ichikawa Y, Nikai H, Tsuru H. Interface histology of unloaded and early loaded partially stabilized zirconia endosseous implant in initial bone healing. *J Prosthet Dent* 1993;69:599–604.
15. Akagawa Y, Hosokawa R, Sato Y, Kamayama K. Comparison between freestanding and tooth-connected partially stabilized zirconia implants after two years' function in monkeys: A clinical and histological study. *J Prosthet Dent* 1998;80:551–558.
16. Ichikawa Y, Akagawa Y, Nikai H, Tsuru H. Tissue compatibility and stability of a new zirconia ceramic in vivo. *J Prosthet Dent* 1992;68:322–326.
17. Kohal RJ, Papavasiliou G, Kamposiora P, Tripodakis A, Strub JR. Three-dimensional computerized stress analysis of commercially pure titanium and yttrium-partially stabilized zirconia implants. *Int J Prosthodont* 2002;15:189–194.
18. Kohal RJ, Weng D, Bächle M, Strub J. Loaded custom-made zirconia and titanium implants show similar osseointegration. *J Periodontol* 2004;75:1262–1268.
19. Kohal RJ, Hürzeler MB, Mota LF, et al. Custom-made root analogue titanium implants placed into extraction sockets. An experimental study in monkeys. *Clin Oral Implants Res* 1997;8:386–392.
20. Sennerby L, Dasmah A, Larsson B, Iverhed M. Bone tissue responses to surface-modified zirconia implants: a histomorphometric and removal torque study in the rabbit. *Clin Implant Dent Relat Res* 2005;7(suppl 1):S13–S20.
21. Wennerberg A. *On Surface Roughness and Implant Incorporation* [thesis]. Göteborg, Sweden: Göteborg University, 1996.
22. De Wijs FLJA, Van Dongen RC, De Lange GL. Front tooth replacement with Tübingen (Frialit) implants. *J Oral Rehabil* 1994;21:11–26.
23. Kohal R J, Klaus G: A zirconia implant/zirconia crown system. A case report. *Int J Periodontics Restorative Dent* 2004;24:147–153.